



# Opponensplasty In Cases With Low Median Nerve Injury

*Thesis*

*Submitted for fulfillment of the M.D. degree in Orthopedic Surgery*

*By*

**Ahmed Ibrahim Mohammad Elkady**

M.B.B.ch, M.Sc

*Under supervision of*

**Prof. Dr. Wael Abdel Aziz Qandil**

Professor of Orthopedic Surgery

Faculty of Medicine

Benha University

**Prof. Dr. Osama Mohammed Essawy**

Assistant professor of Orthopedic Surgery

Faculty of Medicine

Benha University

**Prof. Dr. Eslam Abdel Shafi Tabl**

Assistant Professor of Orthopedic Surgery

Faculty of Medicine

Benha University

Benha University  
Faculty of Medicine

**2021**

# Acknowledgement

*First and foremost thanks to Allah whose magnificent help was the main factor in accomplishing this work.*

*I would like to express my sincere thanks and deepest gratitude to Prof. Dr. Wael Abdel Aziz Qandil Professor of Orthopedic Surgery Faculty of Medicine Benha University , for his kind supervision, limitless support, valuable guidance and continuous encouragement throughout this work.*

*I am also deeply grateful and would like to express my sincere thanks and deepest gratitude to Prof. Dr. Osama Mohammed Essawy Assistant professor of Orthopedic Surgery Faculty of Medicine Benha University , for his guidance and care which allowed the suitable performance of this work.*

*I am also deeply grateful and would like to express my sincere thanks and deepest gratitude to Prof. Dr. Eslam Abdel Shafi Tabl Assistant Professor of Orthopedic Surgery Faculty of Medicine Benha University , for his guidance and care which allowed the suitable performance of this work.*

*Ahmed Ibrahim Mohammad Elkady*

**2021**

## *Table of contents*

<i>Contents</i>	<i>Page</i>
<b>List of abbreviations</b>	<b>I</b>
<b>List to tables</b>	<b>II</b>
<b>List of figures</b>	<b>III</b>
<b>Introduction</b>	<b>1</b>
<b>Aim of the study</b>	<b>3</b>
<b>Review of literature</b>	<b>4</b>
<b>Patients and methods</b>	<b>49</b>
<b>Results</b>	<b>55</b>
<b>Discussion</b>	<b>62</b>
<b>Recommendations</b>	<b>66</b>
<b>Summary &amp; Conclusion</b>	<b>67</b>
<b>References</b>	<b>69</b>
<b>Arabic summary</b>	<b>-1-</b>

## *List Of Abbreviations*

<i>Abbreviations</i>	<i>Means</i>
<b>MCP</b>	Metacarpophalangeal
<b>CMC</b>	carpometacarpal
<b>TM</b>	Trapeziometacarpal
<b>IP</b>	interphalangeal
<b>PIP</b>	Proximal interphalangeal
<b>DIP</b>	Distal interphalangeal
<b>FDS</b>	flexor digitorum superficialis
<b>FDP</b>	flexor digitorum profundus
<b>FCR</b>	flexor carpi radialis
<b>FCU</b>	flexor carpi ulnaris
<b>OPP</b>	opponens pollicis
<b>FPB</b>	flexor pollicis brevis
<b>FPL</b>	flexor pollicis longus
<b>EPB</b>	extensor pollicis brevis
<b>EPL</b>	extensor pollicis longus
<b>APB</b>	Abductor Pollicis Brevis
<b>APL</b>	abductor pollicis longus
<b>ADP</b>	adductor pollicis
<b>PL</b>	palmaris longus
<b>FR</b>	flexor retinaculum
<b>EIP</b>	extensor indicis proprius
<b>ADM</b>	abductor digiti minimi
<b>ECRL</b>	extensor carpi radialis longus
<b>EDC</b>	extensor digitorum communis

## *List of tables*

<i>No.</i>	<i>Tables</i>	<i>Page</i>
<b>1</b>	Satisfaction rate of opponensplasty	<b>31</b>
<b>2</b>	Demographic characteristics of the studied patients	<b>55</b>
<b>3</b>	Mode of injury in the studied patients	<b>56</b>
<b>4</b>	Laterality of injured hand in the studied patients	<b>57</b>
<b>5</b>	Injury to surgery time in the studied patients	<b>58</b>
<b>6</b>	Kapandji score before, after 3 & 6 months in the studied patients	<b>58</b>
<b>7</b>	VAS score before, after 3 & 6 months in the studied patients	<b>59</b>
<b>8</b>	QuickDASH score before, after 3 & 6 months in the studied patients	<b>61</b>

## *List of figures*

<i>No.</i>	<i>Figures</i>	<i>Page</i>
<b>1</b>	Osteoarticular column of the thumb	<b>4</b>
<b>2</b>	The left trapezium. (a) From the dorsal aspect, (b) from the palmar aspect, (c) from the radial aspect, (d) from the medial aspect.	<b>5</b>
<b>3</b>	The left first metacarpal bone	<b>6</b>
<b>4</b>	The articular surfaces in the Trapeziometacarpal joint of the left thumb	<b>8</b>
<b>5</b>	The articular surfaces in the metacarpophalangeal joint of the left thumb	<b>9</b>
<b>6</b>	The articular surfaces in the interphalangeal joint of the left thumb	<b>10</b>
<b>7</b>	Intrinsic muscle of the thumb	<b>12</b>
<b>8</b>	The left thumb flexor sheath	<b>14</b>
<b>9</b>	Dorsal aponeurosis of the right thumb. (FPB flexor pollicis brevis; APB abductor pollicis brevis; EPB extensor pollicis brevis; EPL extensor pollicis longus; ADP adductor pollicis).	<b>15</b>
<b>10</b>	Schematic of the median nerve showing levels of major branching (left column) and muscle units supplied (right column). Origin of root fibres is indicated at the top (C cervical, T thoracic).	<b>18</b>
<b>11</b>	A significant first web space contracture developed after a direct injury to the thenar area and a median nerve laceration. This was released before opponensplasty by using a dorsal rotation flap and skin graft. Postoperatively, the position of the thumb was maintained with a threaded Steinmann pin.	<b>29</b>
<b>12</b>	Extensor indicis proprius is delivered into a dorsoulnar wrist incision and passed through a subcutaneous tunnel around the wrist to an incision over the thumb metacarpophalangeal joint, and then it is sutured to the abductor pollicis brevis tendon.	<b>36</b>
<b>13</b>	EIP opponensplasty. (A) A dorsal transverse incision is made just proximal to the MCP joint of the index finger, and the EIP is identified just ulnar and deep to the EDC. It is transected just proximal to the sagittal bands. (B, C) Identification of the EIP musculotendinous junction through an incision made over fourth extensor compartment. Fascial attachments are divided and the EIP is pulled proximally into this incision. As in this patient, occasionally the EIP will not	<b>37</b>

	<p>glide smoothly between these 2 incisions, and a counter incision over the dorsal radial mid hand should be used to identify and divide any persistent fascial attachments. (D) A subcutaneous tunnel is developed around the ulna, and (E) also between the pisiform and the insertion site over the radial border of the thumb MCP. In the setting of a concurrent carpal tunnel release, as in this patient, an extensile carpal tunnel incision replaces the need for an incision just proximal to the pisiform. The EIP is passed subcutaneously around the ulna, into the carpal tunnel incision, then to the incision at the radial border of the thumb. (F) The tendon is sutured into place. (G) Appropriate tensioning results in the thumb resting palmarly abducted and opposite the index and middle fingers with the wrist at neutral.</p>	
<b>14</b>	<p>The window in the palmar fascia overlying the neck of the third metacarpal is used as a pulley, and the flexor digitorum superficialis transfer is attached to the abductor tubercle of the thumb</p>	<b>39</b>
<b>15</b>	<p>FDS opponensplasty in an 87-year-old man with combined end-stage carpal tunnel syndrome, profound thenar atrophy, and ulnar neuropathy, absent palmaris, with intact ring finger FDS/FDP on preoperative examination. (A) The FDS is harvested through an incision over the ring finger A1 pulley. (B, C) Once the FDS is isolated, the finger is fully flexed, proximal traction on the FDS typically allows for visualization of the bifurcation of FDS at Camper chasm, and the FDS is transected. A several-centimeter incision can be made over the most distal aspect of the FCU (A, dotted line). (D) In this setting of a concurrent carpal tunnel release, both the proximal FDS and FCU can be accessed through an extensile carpal tunnel incision in lieu of a separate incision directly over the FCU. (E, F) A loop pulley is created in the FCU by transecting the radial one-half of a split approximately 5 cm proximal to the pisiform, and suturing this radial slip to the intact ulnar half of the FCU distally. The FDS is passed around the ulnar intact half and then through the loop. (G) The tendon is then passed through a subcutaneous tunnel to the radial aspect of the thumb MCP, where a third incision is made and the FDS is either inserted into the ulnar base of the proximal phalanx or directly attached to the APB tendon. (H) The transfer is tensioned</p>	<b>40</b>

	such that passive wrist extension will result in full thumb opposition.	
<b>16</b>	Postoperative results FDS opponensplasty. (A) Complete opposition restored. (B) Comparative photo with the right hand showing equal pronation of both thumbs.	<b>41</b>
<b>17</b>	The palmaris longus is detached with a strip of palmar aponeurosis and attached to the abductor pollicis brevis insertion	<b>42</b>
<b>18</b>	PL opponensplasty (Camitz transfer) in an 81-year-old man with end-stage carpal tunnel syndrome and profound thenar atrophy. (A) An extensile carpal tunnel incision is made. (B) The PL is elongated with a 1.0-cm-wide to 1.5-cm-wide strip of palmar fascia. (C–E) A generous subcutaneous tunnel is then created between the distal forearm and the dorsoradial aspect of the thumb MCP joint, and an incision is made overlying the APB insertion, taking care to preserve the branch's radial sensory nerve. (C) The PL can be passed through a slit in the ulnar leaf of the release transverse carpal ligament to effect an appropriate pulley. (E, F) The fascial extension is then sutured to the APB tendon with the thumb placed in full passive abduction while the wrist is held neutral.	<b>43</b>
<b>19</b>	Postoperative PL opponensplasty thumb abduction was restored; even some pronation was restored.	<b>44</b>
<b>20</b>	Abductor digiti minimi is detached with neurovascular structures while preserving an attachment to the flexor carpi ulnaris. The abductor digiti minimi is rotated on its long axis and passed subcutaneously and attached to the adductor pollicis brevis.	<b>45</b>
<b>21</b>	ADM opponensplasty in a 2-year-old with hypoplastic thumb. (A, B) An incision is designed extending from the ulnar base of the small finger to a point just proximal to the pisiform, exposing the entire broad muscle belly of the ADM. (C) The ADM insertion into the proximal phalanx and extensor mechanism is incised. (D) A generous subcutaneous tunnel is created toward a second incision made over the APB insertion of the thumb, and (E) the ADM is passed through the tunnel.	<b>46</b>
<b>22</b>	Postoperative results ADM opponensplasty. (A) No loss of adduction. (B) Full abduction restored. (C) Complete opposition	<b>47</b>
<b>23</b>	Kapandji score. (a) Numbered fingers to establish the	<b>51</b>



	opposition score. <b>(b)</b> The thumb touches only the middle phalanx of the index, Kapandji score is 2. <b>(c)</b> The thumb touches the distal palmar flexion creases, Kapandji score is 10	
<b>24</b>	Gender distribution of the studied patients	<b>55</b>
<b>25</b>	Mode of injury in the studied patients	<b>56</b>
<b>26</b>	Laterality of injured hand in the studied patients	<b>57</b>
<b>27</b>	Kapandji score before, after 3 & 6 months in the studied patients	<b>59</b>
<b>28</b>	VAS score before, after 3 & 6 months in the studied patients	<b>60</b>
<b>29</b>	QuickDASH score before, after 3 & 6 months in the studied patients	<b>61</b>

## **INTRODUCTION**

Opposition is the placement of the thumb opposite the fingers into a position from which it can work. This motion requires thumb palmar abduction, flexion, and pronation, which are provided by the abductor pollicis brevis, flexor pollicis brevis, and opponens pollicis. <sup>(1)</sup>

There are many potential causes of median nerve palsy, and thus a lack of opposition. These include acute median nerve laceration or damage from trauma as well as chronic median nerve compression from carpal tunnel syndrome, pronator syndrome, or cervical radiculopathy. Also, congenital absence of thenar musculature is common with radial longitudinal deficiency and thumb hypoplasia. Many neurologic conditions, such as Charcot-Marie-Tooth, chronic inflammatory demyelinating polyneuropathy, and leprosy, frequently result in thenar muscle atrophy as well. Less common etiologies would include tumor or brachial plexopathies. <sup>(2)</sup>

*In* a low median nerve palsy, the thumb rests in constant unopposed external rotation and supination. Over time, in the absence of passive stretching exercises, this may result in progressive shortening and contracture of the dorsal first web space skin and fascia with resultant stiffness. If present, surgery to restore opposition must include elongation of the first web space skin and fascia with either z-plasty or skin graft. Contracture of the first web space will further place the MCP joint of the thumb at a biomechanical disadvantage and further predispose it to hyperextension deformity. <sup>(3)</sup>

Opponensplasty is a commonly used tendon transfer to restore thumb opposition. The flexor digitorum superficialis (FDS) of the ring finger is

the most commonly used donor motor unit in cases of low median nerve palsy. If the FDS is not available, the extensor indicis proprius is usually chosen for the transfer. In patients with severe carpal tunnel syndrome and loss of thumb opposition, simultaneous carpal tunnel release and palmaris longus opponensplasty are frequently performed. Finally, the abductor digiti minimi opponensplasty is often done in congenital hypoplasia of the thenar muscles because it has the advantage of adding thenar bulk. <sup>(4)</sup>

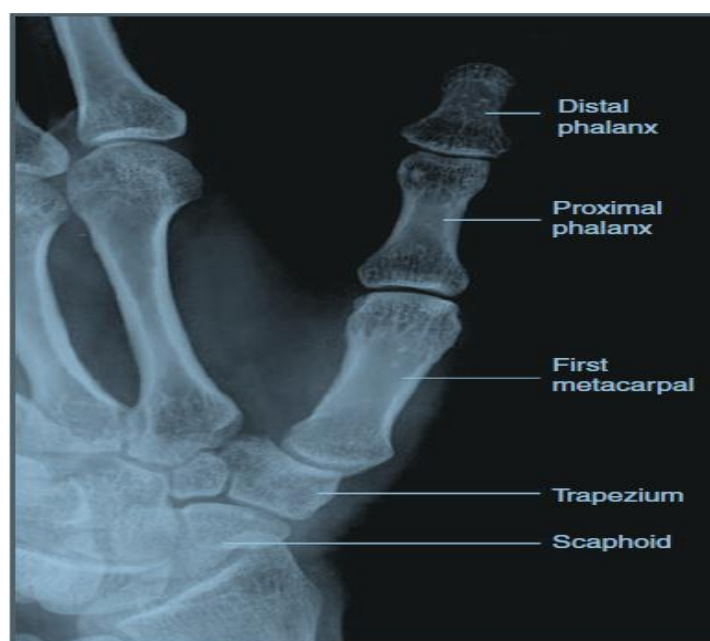
## **AIM OF THE WORK**

The aim of this randomized study is to assess the outcome of tendon transfer for restoration of opposition in cases of low median nerve injury regarding hand grip and range of motion and functional outcome.

.

## **Bones The thumb:**

Osteoarticular column of the thumb is formed from the whole of the lateral ray of the hand (Figure 1). Therefore, it begins with the scaphoid, passing then to the trapezium. After this comes the first metacarpal, and finally it ends with only two phalanges. Thus, the thumb has an important characteristic that the column itself articulates with the rest of the hand at a point much more proximal than the other digits. Also it is clearly much shorter than they are, since the tip of the thumb reaches only the middle of the proximal phalanx of the index finger. <sup>(5)</sup>



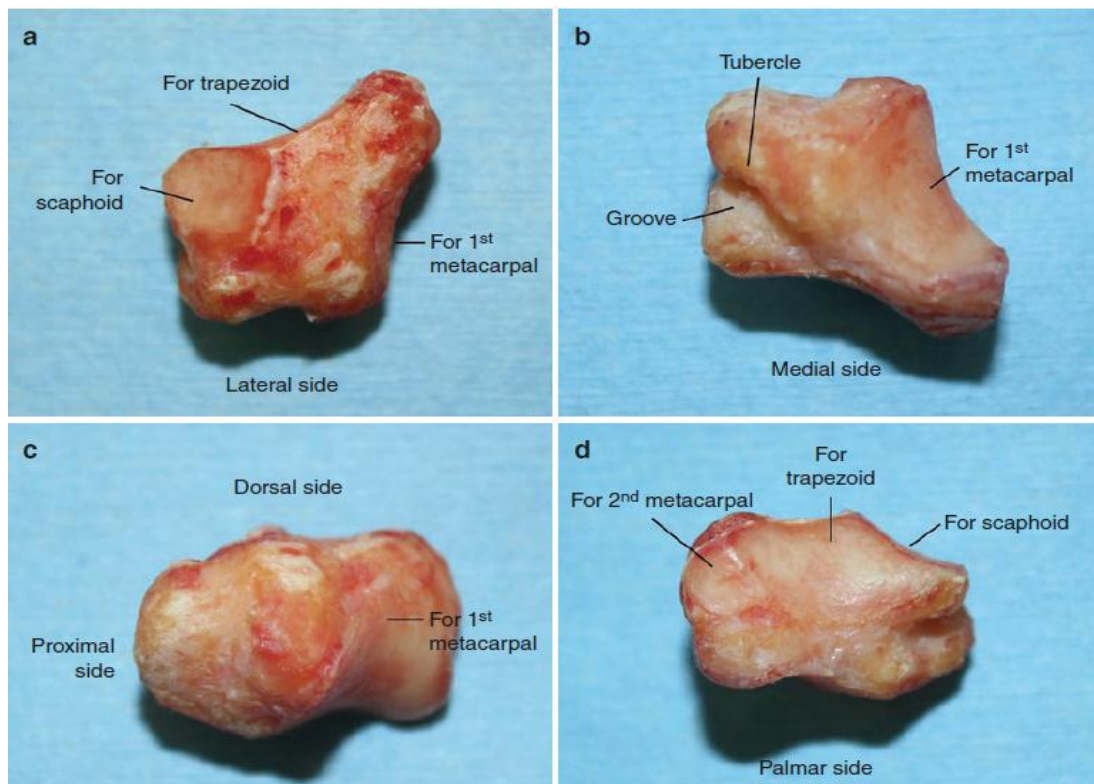
**Figure 1:** Osteoarticular column of the thumb. <sup>(5)</sup>

## **Trapezium:**

Trapezium changes its shape from proximal to distal; owing to this characteristic, it is called a multiangular bone. The bone is situated at the radial column of the wrist between the scaphoid and first metacarpal. <sup>(6)</sup>

The proximal surface is smooth and contains a small, slightly concave facet which articulates with the scaphoid. The distal surface is

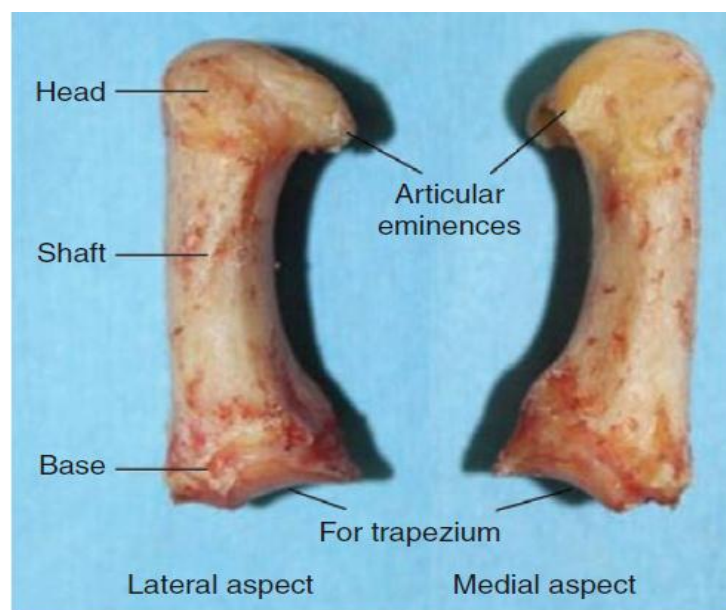
oval and saddle shaped and faced distolaterally. It articulates with the base of the first metacarpal. The dorsal surface is elongated and rough and rests in relationship to the radial artery. The palmar surface is narrow and rough. At its palmar part is a deep groove, which is medial and contains the flexor carpi radialis (FCR) tendon. The groove is bounded laterally by a tubercle. This surface gives origin to the opponens pollicis (OPP), flexor pollicis brevis (FPB), and APB and provides attachment to the two layers of the flexor retinaculum. The lateral surface is broad and rough for the attachment of the radial collateral ligament and capsular ligament of the carpometacarpal (CMC) joint of the thumb. The medial surface is large and presents two facets: a large, concave, proximal one, which articulates with the trapezoid, and a small, distal one, which articulates with the second metacarpal (Figure 2).<sup>(6)</sup>



**Figure 2:** The left trapezium. (a) From the dorsal aspect, (b) from the palmar aspect, (c) from the radial aspect, (d) from the medial aspect.<sup>(6)</sup>

**First Metacarpal:**

The first metacarpal bone is short and broad. Its long axis diverges distolaterally from the other metacarpals. It is more anterior and rotated medially on its long axis through 90°, so that its palmar surface is directed medially toward the radial side of the second metacarpal and its dorsal surface is directed laterally. The shaft is flattened and broad, and its dorsal surface is slightly convex. Its palmar surface is concave and divided by a ridge into a larger lateral (anterior) part, which gives attachment of the OPP, and a smaller medial (posterior) part, which gives origin to the radial head of the first dorsal interosseous muscle. The base has a characteristic saddle-shaped articular surface for articulation with trapezium. It has a small tubercle on its lateral side for the insertion of the abductor pollicis longus (APL). The head is rounded and less convex than in other metacarpals and is transversely broad. Two articular eminences are on the palmar surface of the head for the sesamoid bones; the lateral is larger than the medial (Figure 3).<sup>(7)</sup>



**Figure 3:** The left first metacarpal bone.<sup>(7)</sup>

### **The Proximal Phalanx:**

The shaft of the proximal phalanx is short, tapers distally, and is convex dorsally. The base presents oval and concave articular surface. Further, it is transversely broad and articulate with the rounded, smooth heads of the metacarpal bone. The head is smaller than the base and ends in two condyles, which are dissimilar, the medial one being more protruding and longer palmarly and medially than its lateral one. <sup>(5)</sup>

### **The Distal Phalanx:**

The distal phalanx is convex on dorsal and flat on palmar surfaces. The base is oval, concave articular surface and articulates with the head of the proximal phalanx. The head of the distal phalanx is non articular and carries a rough, horse-shaped palmar tuberosity, called the unguis tuberosity, to which the pulp of the thumb tip is attached. <sup>(5)</sup>

## **Joints of the Thumb:**

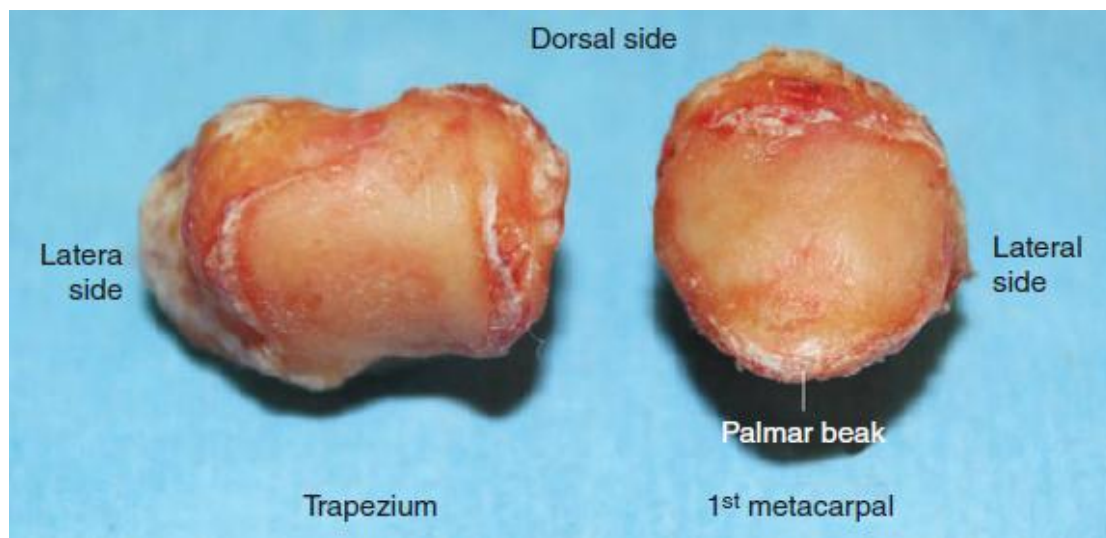### **Trapeziometacarpal Joint (TM Joint):**

The TM joint of the thumb is a biconcave-convex or reciprocal saddle joint. The trapezium articular surface is in convex from dorsal to palmar and concave from radial to ulnar, and the midsagittal diameter is  $11.96 \pm 1.32$  mm. The joint surface is actually asymmetrical, and the articulating surface is located mainly on the volar aspect. <sup>(8)</sup>

The trapezium and first metacarpal articulate such that the concave surface of the trapezium opposes the convex surface of the first metacarpal (figure 4). As a result, it configures an interlocking appearance and two reciprocally opposed saddles, whose longitudinal



axes are perpendicular. This configuration allows flexion and extension axis as well as an abduction and adduction axis. <sup>(9)</sup>



**Figure 4:** The articular surfaces in the Trapeziometacarpal joint of the left thumb. <sup>(9)</sup>

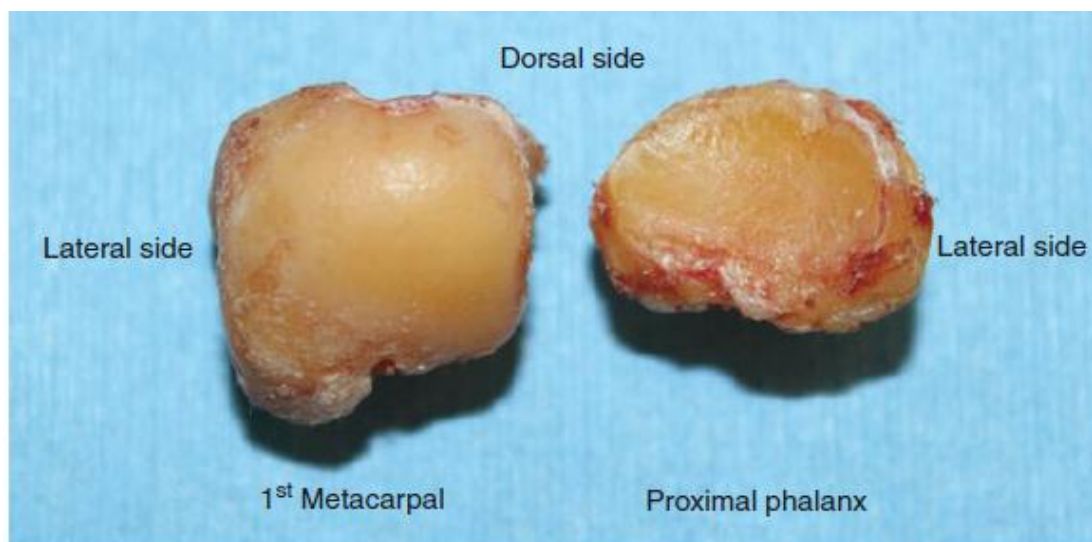
### **Metacarpophalangeal Joint (MCP Joint):**

The MCP joint of the thumb is not a hinge but a condylar joint. This joint is different from the MCP joint of the other fingers, because it has the following characteristics: (1) it has constant presence of sesamoids, (2) it has the vicinity of the insertions of the thenar muscles, and (3) it has lesser mobility, in the flexion-extension and in the abduction-adduction planes. These differences are related to the main role of this joint, namely, to stabilize the thumb in power grip, especially by locking the thumb in the grasping of large objects. <sup>(10)</sup>

The articular surface configuration of the first metacarpal head is more quadrilateral and less sphenoidal than the other metacarpals. The medial condyle extends slightly more distally than the lateral condyle, which accounts for the small amount of pronation that occurs with joint flexion. The chief difference is that the surface spreads over the palmar

tubercles which protrude condyle-like (especially the lateral one) to correspond to the sesamoids. <sup>(10)</sup>

The articular surface of the base of the proximal phalanx is oval, shallow concave and transversely broad (Figure 5). The difference in the area of contact between the two articular surfaces permits usually less flexion and extension (average 53° of flexion and 8° of extension), and there is limitation in abduction and adduction (average 10°) than in fingers. Rotation is restricted by its ligamentous structures. <sup>(10)</sup>



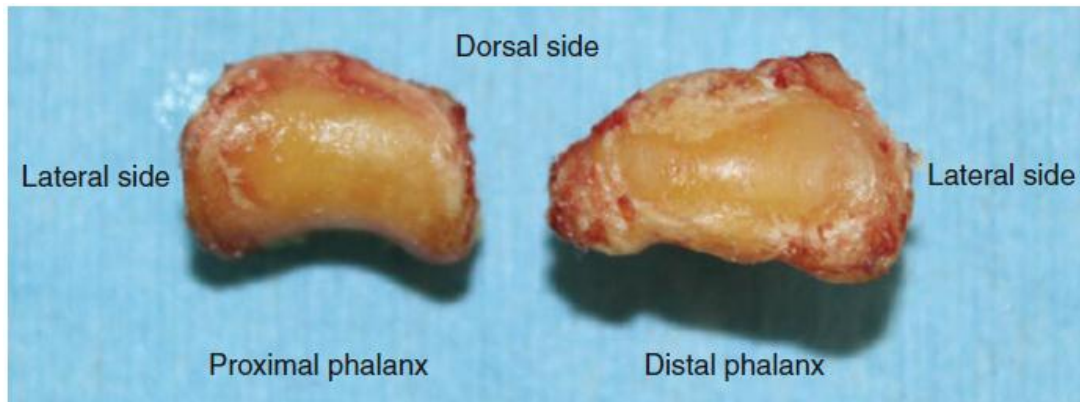
**Figure 5:** The articular surfaces in the metacarpophalangeal joint of the left thumb. <sup>(10)</sup>

### **Interphalangeal Joint (IP Joint):**

The interphalangeal joint of the thumb is a simple hinge joint. It had a single fixed transverse axis, which passes through the center of curvature of the condyles of the phalangeal head, around which flexion-extension movement occurs in a range of 90°. <sup>(10)</sup>

In practice, as it flexes, the distal phalanx undergoes 5–10° of pronation due to the asymmetry of the two condyles of the proximal phalanx. The medial condyle protrudes further distally and palmarly than

the lateral condyle (Figure 6). Its ligamentous structure is similar to the IP joints of the fingers. However, the volar plate is significantly thicker and displaces the FPL tendon for palmarward from the joint space. A sesamoid is sometimes embedded in the volar plate. <sup>(10)</sup>



**Figure 6:** The articular surfaces in the interphalangeal joint of the left thumb. <sup>(10)</sup>

## **Anatomy of Thumb Muscles and Tendons:**

The nine motor muscles act on the thumb. Every joint can be moved by itself or together with others. All forces exerted by the muscles act as dynamic stabilizers of the thumb, facilitating pinch and grasp function.

**It may be divided into two groups:**

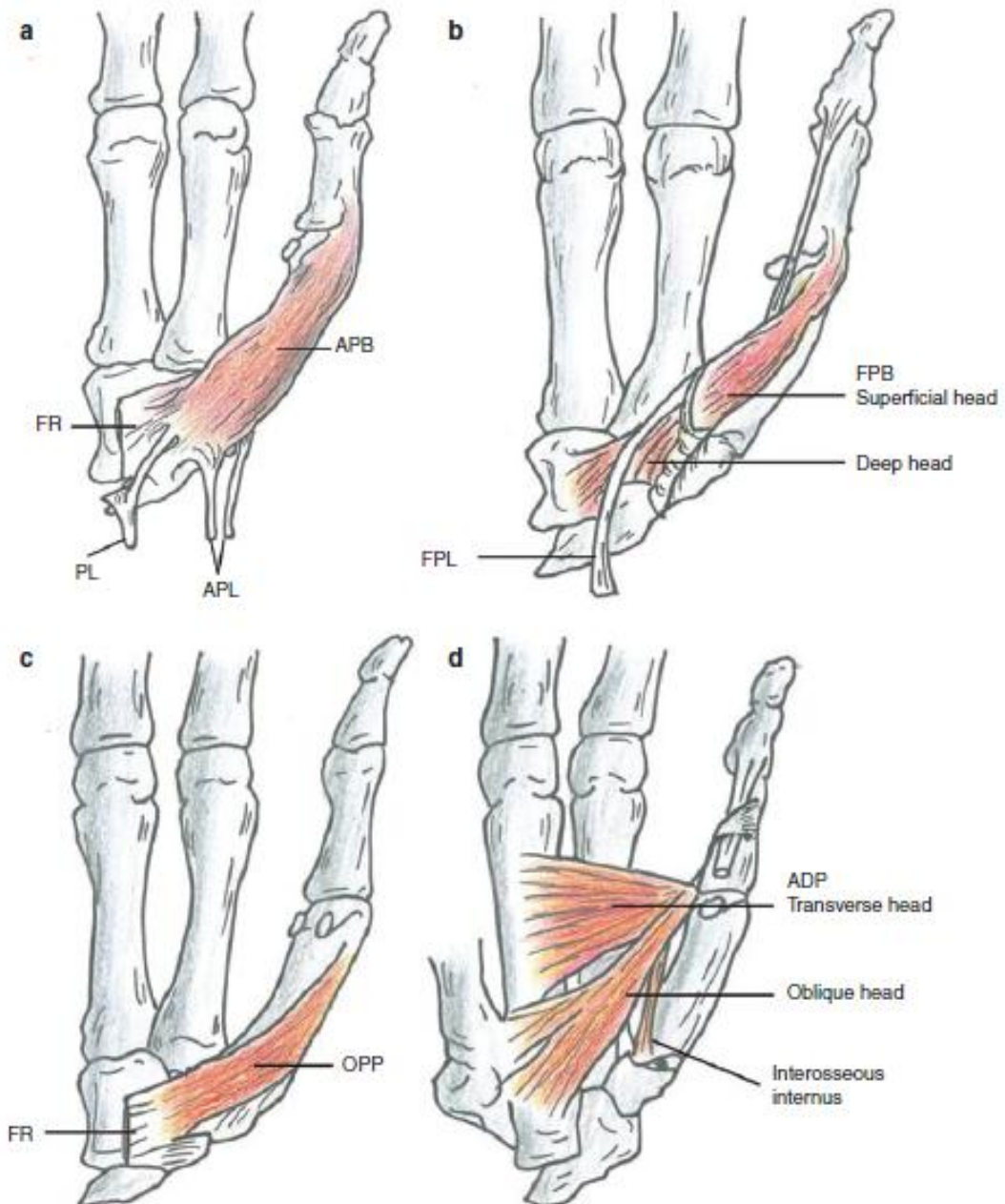
1. The intrinsic muscles, which are situated in the thenar eminence and work simultaneously on the TM, MP, and IP joints. Therefore, they are responsible for performing the different types of grip. These muscles include APB, FPB, OPP, and ADP.
2. The extrinsic muscles, whose muscle bellies are situated in the forearm. These muscles include APL, EPB, EPL and FPL. They are responsible for thumb motion and stability and are the ones used to release the grip except the FPL. <sup>(11)</sup>

## **Intrinsic Muscles:**

**Abductor Pollicis Brevis (APB):** It lies directly beneath the skin and radial to the FPB. It provides the shape and contour of the radial side of the thenar eminence. APB arises primarily from the flexor retinaculum. Accessory bundles of fibers may also arise from the scaphoid tubercle, the trapezium, and the tendons of palmaris longus (PL) and APL. It inserts into the radial base of the proximal phalanx, the lateral side of the capsule of the MP joint, and the radial sesamoid at the MP joint and onto the dorsal aponeurosis of the extensor pollicis longus (Figure 7a).<sup>(9)</sup>

**Flexor Pollicis Brevis (FPB)** It lies medial to the APB and has superficial (lateral) and deep (medial) heads. The tendon of the FPL separates the muscle into two parts. The superficial head arises from the distal border of the flexor retinaculum and the tubercle of the trapezium, passing radially to the tendon of the FPL. It inserts on the radial base of the proximal phalanx. The deep head arises from the trapezoid, capitate, and palmar ligaments of the distal carpal row, passing deep to the tendon of the FPL, and inserts into the radial sesamoid and the base of the proximal phalanx. An expansion of the tendon inserts onto the dorsal apparatus of the thumb (Figure 7b).<sup>(10)</sup>

**Opponens Pollicis (OPP):** It is a short and thick muscle that lies mostly deep into the APB. It arises from the flexor retinaculum, CMC joint capsule, and the tubercle of trapezium and fans out to insert on the whole-length volar radial aspect of the first metacarpal (figure 7c).<sup>(11)</sup>



**Figure 7:** Intrinsic muscle of the thumb.

- (a) Abductor pollicis brevis,
- (b) flexor pollicis brevis,
- (c) opponens pollicis,
- (d) Adductor pollicis.

(APB abductor pollicis brevis; FR flexor retinaculum; PL palmaris longus; APL abductor pollicis longus; FPB flexor pollicis brevis; FPL flexor pollicis longus; OPP opponens pollicis; ADP adductor pollicis).<sup>(5)</sup>

**Adductor Pollicis (ADP):** It is the largest, most powerful thenar muscle and arises by two heads, an oblique and a transverse head. The transverse head is a triangular muscle arising from the distal two thirds of the palmar surface of the third metacarpal. The oblique head usually arises from the base of the second and third metacarpals, capitate, trapezoid, palmar intercarpal ligament, and the sheath of the flexor carpi radialis tendon. The two heads converge, and their fibers rotate so that the transverse head inserts mainly into the ulnar base of the proximal phalanx and ulnar sesamoid of the MP joint, while the oblique head inserts mainly into the dorsal extensor apparatus. An oblique bundle of fibers runs from the ulnar sesamoid across the FPL tendon and reinforces its fibrous sheath (figure 7d).<sup>(5)</sup>

**First Palmar Interosseous Muscle :** It arises from the ulnar side of the base of the first metacarpal and inserts into the ulnar sesamoid of the MP joint, and it is often rudimentary .<sup>(6)</sup>

### **Extrinsic Muscles:**

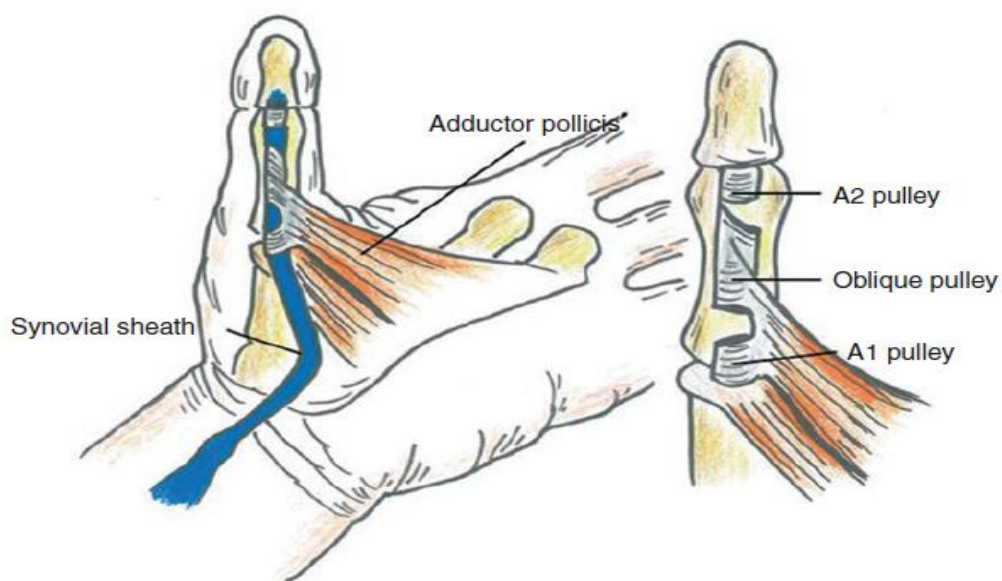
**Flexor Pollicis Longus (FPL):** The fibrous sheath for the FPL begins at the wrist approximately 2.0 cm proximal to the radial styloid and ends just distal to the IP joint. The fibrous sheath is a double-walled hollow tube and lined by a thin synovial membrane that provides a sealed lubrication system containing synovial fluid. The fibrous wall layer is reinforced by ligamentous pulleys. There are three constant pulleys: two annular and one oblique (Figure 8).<sup>(5)</sup>

The A1 annular pulley is located at the MP joint. It is stronger, 7–9 mm wide, and about 0.5 mm thick. Its proximal two thirds fused with the volar plate of the MP joint, and its distal one third fused with the base of the proximal phalanx.<sup>(12)</sup>

The A2 annular pulley is located just proximal to the IP joint and is fused with volar plate of the IP joint. It is slightly wider (8–10 mm) but significantly thinner (0.25 mm).<sup>(12)</sup>

The oblique pulley begins at the ulnar aspect of the base of the proximal phalanx and continues in a distal and oblique direction to end on the radial aspect of the proximal phalanx near the IP joint. It is 9–10 mm wide and about 0.5–0.15 mm thick. The proximal end of the oblique pulley arises from one portion of the inserting tendons of the ADP. The oblique pulley is the most important pulley in the thumb for preserving normal flexion of the thumb.<sup>(12)</sup>

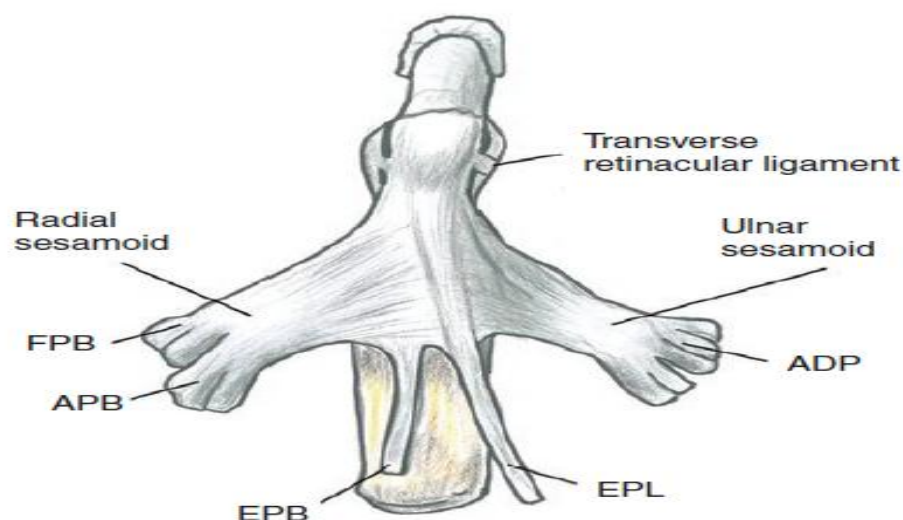
The inserting tendon of the FPL passes through the carpal tunnel. At the thenar eminence, it is located between the OPP and the oblique head of the ADP. It inserts into the palmar surface of the base of the distal phalanx. During the course, it is accompanied by carpal, metacarpal, and phalangeal mesotendons that occur in the form of short and long vincula.<sup>(12)</sup>



**Figure 8:** The left thumb flexor sheath.<sup>(5)</sup>

**Extensor Pollicis Longus (EPL):** The tendon of the EPL is formed just proximal to the wrist and passes through the third extensor compartment. After it turns around the Lister's tubercle, it obliquely crossed the extensor carpi radial longus and brevis; with slight ulnar displacement, it then continues obliquely to the center of the MP joint and past the center of the proximal phalanx and is attached to the dorsal base of the distal phalanx. <sup>(5)</sup>

The transverse retinacular ligament is a thin membrane that arises from the flexor tendon sheath immediately distal to the MP joint. It inserts into the dorsal aponeurosis over the proximal phalanx. The oblique retinacular ligament arises from the lateral margin of the base of the proximal phalanx and from the tendon of the APB and ADP. It traverses the MP joint palmar to dorsal and reaches the EPL tendon at the distal half of the proximal phalanx and inserts the tendon into the distal phalanx (Figure 9). Both retinacular ligaments control the dorsal aponeurosis of the thumb. <sup>(5)</sup>



**Figure 9:** Dorsal aponeurosis of the right thumb. (*FPB* flexor pollicis brevis; *APB* abductor pollicis brevis; *EPB* extensor pollicis brevis; *EPL* extensor pollicis longus; *ADP* adductor pollicis). <sup>(5)</sup>



**Extensor Pollicis Brevis (EPB)** This tendon runs between APL and EPL and is inserted into the base of the proximal phalanx (Figure 9). Because the EPB and the EPL tendon are two separate tendons, it is possible to extend the MP and IP joints independently of one another. It is innervated by the posterior interosseous nerve. It extends up to the proximal phalanx and first metacarpal. <sup>(5)</sup>

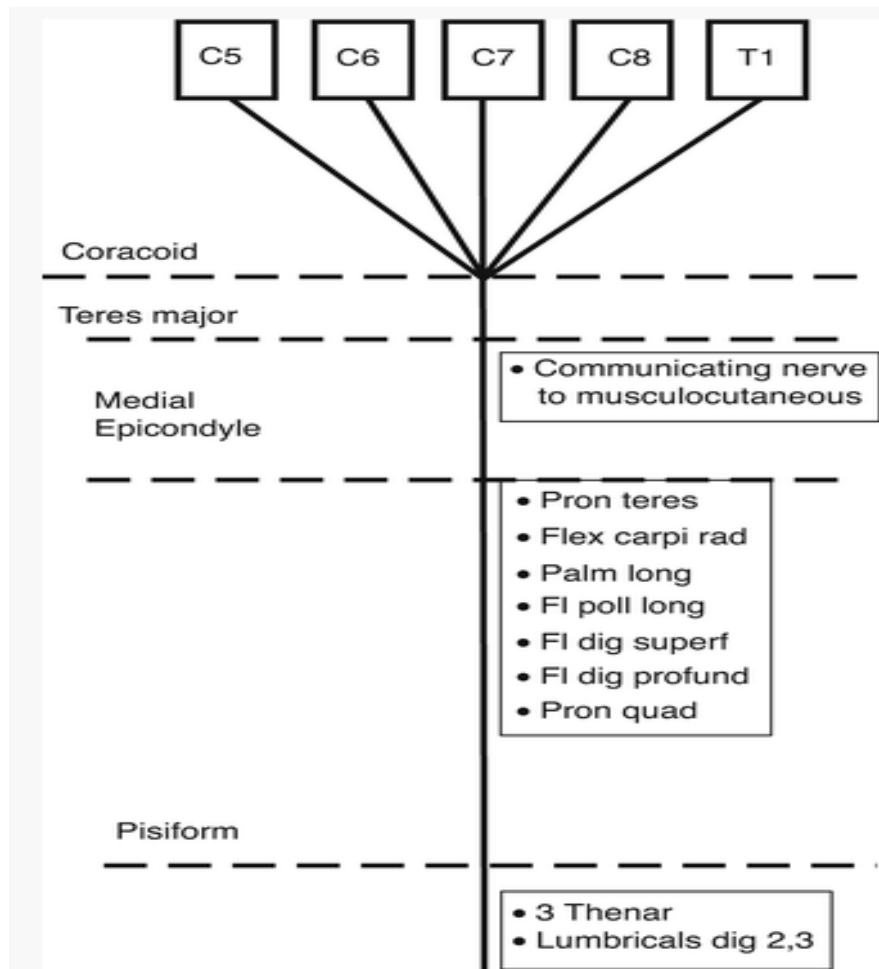
**Abductor Pollicis Longus (APL)** This tendon is formed just proximal to the wrist and runs under the first extensor compartment, accompanied by the tendon of EPB. It usually splits into two slips: one is inserted into the base of the first metacarpal and the other is inserted into the trapezium. It is innervated by the posterior interosseous nerve. It is a pure extensor of the TM joint and abducts the first metacarpal. <sup>(5)</sup>

### **Anatomy of Median nerve:**

The median nerve is a mixed nerve, which is used for pronation of the forearm, wrist flexion and use of the first three digits. The median nerve arises by two roots, one lateral root (C5, 6, 7) from the lateral cord and one medial root (C8, T1) from the medial cord. The medial root tends to be constant in size and course, while the lateral root can vary. If the lateral root is small, the musculocutaneous nerve often sends a communicating branch to the median nerve. The roots embrace the third part of the axillary artery, uniting either in front or on the lateral side of the artery. Frequently, some of the fibres derived from C7 leave the lateral root in lower part of the axilla and pass distally and medially behind the medial root and usually in front of the axillary artery to join the ulnar nerve. These fibres from C7 may arise from the lateral cord or even directly from the seventh cervical nerve root of the brachial plexus.

These are believed to be mainly be motor fibres to the flexor carpi ulnaris (Figure 10).<sup>(13)</sup>

The median nerve descends into the arm, lying at first lateral to brachial artery. About the level of insertion of the coracobrachialis, it crosses in front of (rarely behind) the artery and descends on its medial side to the cubital fossa where it lies behind the bicipital aponeurosis and in front of the brachialis. The median nerve enters the forearm from the cubital fossa by passing between the two heads of the pronator teres muscle. In the upper third of the forearm, it may communicate with the ulnar nerve (in about 15 % of cases). It descends deep to the flexor digitorum superficialis to which it is closely attached by the muscles fascial sheath and then continues distally between this muscle and the flexor digitorum profundus. Near the wrist the median nerve becomes superficial by passing between the tendons of the flexor digitorum superficialis and the flexor carpi radialis, deep to the tendon of the palmaris longus (if present). Here it can be easily palpated just before it passes deep to flexor retinaculum. The median nerve passes supplies primarily flexor muscles of the forearm, five muscles in the hand and the skin of the hand.<sup>(13)</sup>



**Figure 10:** Schematic of the median nerve showing levels of major branching (*left column*) and muscle units supplied (*right column*). Origin of root fibres is indicated at the top (*C* cervical, *T* thoracic).<sup>(13)</sup>

### Path anatomy of median nerve injury:

High median nerve injury occurs proximal to the elbow joint and leads to weakness of:

1. Thumb opposition secondary to denervation of the superficial head of the flexor pollicis brevis (FPB), abductor pollicis brevis (APB), and the opponens pollicis
2. Thumb interphalangeal (IP) flexion secondary to denervation of the flexor pollicis longus (FPL)

3. Distal interphalangeal (DIP) flexion secondary to denervation of the index and long finger flexor digitorum profundus (FDP)
4. Proximal interphalangeal (PIP) flexion secondary to denervation of the flexor digitorum superficialis (FDS)
5. Forearm pronation secondary to denervation of the pronator teres and pronator quadratus
6. Wrist flexion secondary to denervation of the flexor carpi radialis (FCR), ulnar deviation occurs with wrist flexion since the flexor carpi ulnaris (FCU) is intact
7. Sensory deficits in the thumb, index, long, and radial half of the ring fingers.

Low median nerve injuries occur distal to the elbow resulting in the following motor and sensory deficits:

1. Thumb opposition secondary to denervation of the superficial head of the FPB, APB, and the opponens pollicis
2. Sensory deficits in the thumb, index, long, and radial half of the ring fingers. <sup>(27)</sup>

## **Mechanics of opposition**

In terms of biomechanical motion, there are seven maneuvers in the hand in order to perform most of the hand function. For the hand function, the opposition is the most important function in the thumb. The axis of the thumb has its foundation at the TM joint and rests in a pronated and flexed position approximately  $80^\circ$  relative to the plane of the other metacarpals. This unique position allows opposition of the thumb to digits. <sup>(14)</sup>

Opposition begins with the thumb in its resting position, a position of  $90^\circ$  pronation to the plane of the fingers. Therefore, for the thumb to achieve maximum opposition, an additional pronation of  $90^\circ$  is required that occurs in a curvilinear manner and encompasses 3 motions: abduction, flexion, and pronation. Abduction occurs primarily at the Trapeziometacarpal (TM) joint and is the angle between the first and second metacarpals in the sagittal plane. At its maximum, the angle approximates  $40^\circ$  to  $50^\circ$ . The contribution of the metacarpophalangeal (MP) joint, a condyloid joint, depends on the degree of normal ligament laxity and the morphology of the joint, especially the head of the metacarpal. The MP joints in fingers are also condyloid joints, but the curvature of the metacarpal heads is significantly greater than the MP joints of thumbs. Finger MP Joints are therefore capable of a wide arc of abduction/adduction. The metacarpal heads in thumb MP joints are usually flat, which limits abduction/adduction; abduction ranges from a few degrees to  $20^\circ$  to  $25^\circ$ . The interphalangeal (IP) joint, a ginglymus or hinge joint, contributes nothing. Total abduction of the thumb is therefore variable and can range from  $40^\circ$  to  $50^\circ$ , provided by the TM joint, to  $70^\circ$  to  $75^\circ$ , when there is also a contribution from the MP joint. <sup>(15)</sup>

The muscles involved in thumb abduction, the first component of opposition, are essentially the intrinsic muscles in the thenar eminence: the abductor pollicis brevis (APB), the superficial or radial head of the flexor pollicis brevis (FPB), and the opponens pollicis. The only thenar muscle not involved in abduction is the deep or ulnar head of the FPB. The extrinsic abductor pollicis longus (APL), despite its name, contributes little. APL's primary function is extension of the thumb ray (in the coronal plane) via its insertion into the base of the first metacarpal. Its contribution to thumb abduction is when a tendon slip(s) inserts volar to the TM joint; this rarely occurs. Rather than abducting the thumb, the APL extends the first metacarpal, which is important for maintaining the longitudinal arch of the thumb. Without that arch, the MP joint usually becomes secondarily hyperextended and the IP joint goes into a flexed position, resulting in a zigzag deformity. This is commonly seen in the patient with TM joint arthritis whose.<sup>(15)</sup>

The flexion component of opposition involves all 3 thumb joints. TM joint flexion permits positioning of the head of the thumb metacarpal in the same sagittal plane as the head of the middle finger metacarpal, MP joint flexion facilitates grasping objects of different sizes with less flexion obviously required for large objects than for small objects, and IP joint flexion depends on the prehensile activity being performed. For pulp-to-pulp pinch, the IP joint is extended or is in slight flexion, and for tip-to-tip pinch, it is in greater flexion. The muscles that contribute to the flexion component of opposition are the intrinsic thumb muscles with the exception of the opponens pollicis, which inserts entirely on the first metacarpal. For forceful flexion, there are important contributions from the adductor pollicis, an intrinsic thumb muscle that is not in the thenar

eminence and is innervated by the ulnar nerve, and from the extrinsic flexor pollicis longus (FPL).<sup>(15)</sup>

The third component of opposition, pronation, occurs around a longitudinal axis through the center of the TM joint. Pronation essentially occurs simultaneously with flexion and abduction of the TM joint caused by the configurations of its articular surfaces and ligaments. The TM joint is a concavoconvex joint that is commonly referred to as a saddle joint. Based on its anatomic configuration, a saddle joint permits motions in 2 planes: flexion/ extension and abduction/adduction. The motions can be compared with a cowboy sitting snugly in a Western saddle who is able to bend forward and backward and shift side to side but is unable to turn because of the high cantle of the saddle in the rear and the prominent horn in the front. For him to turn or rotate, the cowboy must first lift himself from the saddle seat by pushing down against the stirrups. It is much easier for a rider to turn in an English saddle, which has a lower cantle and no horn. The articular surfaces of a human saddle joint (TM joint) are shallow and therefore more closely resemble an English saddle than a Western saddle. It is the shallow articular configurations and the anatomy of the ligaments that provide sufficient laxity to the TM joint to permit rotation, often referred to as circumduction, the third component of opposition.<sup>(15)</sup>

For opposition (a combination of abduction, flexion, and pronation) to be effective, the thenar intrinsic muscles, including the APB, radial head of the FPB, and opponens pollicis, must function. The APB is the most important muscle for opposition. It abducts, flexes, and rotates the metacarpal; abducts and flexes the proximal phalanx; and extends the IP joint. The radial head of the FPB is a weak abductor that is not nearly as effective as the APB, and the opponens pollicis is even less effective. The

opponens pollicis abducts, flexes, and rotates the metacarpal similar to the APB but has no effect distal to the MP joint because its insertion is solely on the first metacarpal. The opponens pollicis is the least important intrinsic muscle for thumb opposition, and is the reason why Emanuel Kaplan, the great anatomist and first Chief of the Division of Hand Surgery at New York University Hospital for Joint Diseases, objected to the term “opponensplasty”. Kaplan taught that when surgery was performed for absence of thenar muscle function, the objective was to restore opposition and not restore function of the opponens pollicis; He often stated, “Why name an operation for the least important thenar muscle?” He preferred the term “opposition tendon transfer” because it accurately described the objective of the procedure; it is the term used by Kaplan’s students and the one taught to residents and fellows.<sup>(15)</sup>



## **Etiology of low median nerve palsy**

There are many potential causes of median nerve palsy, and thus a lack of opposition. These include acute median nerve laceration or damage from trauma as well as chronic median nerve compression from carpal tunnel syndrome, pronator syndrome, or cervical radiculopathy. Also, congenital absence of thenar musculature is common with radial longitudinal deficiency and thumb hypoplasia. Many neurologic conditions, such as Charcot-Marie-Tooth, chronic inflammatory demyelinating polyneuropathy, and leprosy, frequently result in thenar muscle atrophy as well. Less common etiologies would include tumor or brachial plexopathies. In all cases of thenar muscle weakness, it is imperative to perform a meticulous sensory examination, as sensory loss can significantly impact the outcomes of tendon transfers.<sup>(16)</sup>

### **Diagnosis:**

#### **Physical examination:**

The best way to assess APB atrophy is to view the thenar musculature from the radial side as opposed to from the traditional palmar side (ie, with the forearm in neutral rather than full supination). The strength of resisted palmar abduction is then tested and noted. It should be remembered that not all patients demonstrate a significant functional deficit in the presence of a median nerve palsy due to cross innervation or patient level of demand. The thumb MP joint should be assessed for hyperextension. The palmar plate of the thumb MP joint serves as a passive restraint to resist hyperextension forces. In a thumb with normal muscle balance, the intrinsic muscles of the thumb guard the joint against excessive load by serving as active restraints. In cases of

muscle paralysis, however, the deprivation of the joint of its dynamic protection may result in gradual attenuation of the palmar plate with resultant MCP hyperextension. Finally, in a low median nerve palsy, the thumb rests in constant unopposed external rotation and supination. Over time, in the absence of passive stretching exercises, this may result in progressive shortening and contracture of the dorsal first web space skin and fascia with resultant stiffness. If present, surgery to restore opposition must include elongation of the first web space skin and fascia with either z-plasty or skin graft. Contracture of the first web space will further place the MCP joint of the thumb at a biomechanical disadvantage and further predispose it to hyperextension deformity. <sup>(16)</sup>

## **Evaluation**

As in all areas of medicine, a thorough physical examination is the most important tool of the diagnostician in the diagnosis of median nerve palsies. In the setting of acute fractures or trauma, x-rays should be employed to assess for concomitant osseous injuries, which may cause injury or compression to the nerve but will have little utility in the assessment of nerve injury.

Ultrasound is a useful tool and may reveal the etiology of nerve compression. Electromyography is another commonly used tool in the diagnosis of compression neuropathies and muscle denervation. Compressive neuropathies result in increased distal latency and decreased conduction velocity when evaluated by EMG. Fasciculations within the innervated musculature are a sign of denervation and warrant a more urgent surgical decompression. <sup>(38)</sup>

## **Patient Counseling**

Although the indication for opponensplasty is loss of opposition, surgery is necessitated by loss of function due to loss of opposition. If the loss of opposition is unilateral, and especially if it affects the non-dominant hand, the consequent loss of function may be minimal and insufficient to warrant surgery. Additionally, if there is loss or absence of sensation in the median nerve territory, this may reduce the potential benefit of opponensplasty because the loss of function is primarily due to the loss of sensation. Careful patient counseling about the possible functional benefits, the rehabilitation process, and the likely outcome of surgery (actual success rates may be less than published success rates for restoration of opposition movement) is mandatory. The surgeon must have a clear picture of the functional disability and be confident that this is due to the loss of opposition and not to other factors, such as sensory impairment or joint stiffness. <sup>(26)</sup>

## **Restoration of Thumb Opposition:**

### **Correction of Thumb Deformity**

The failure to detect an established adduction contracture of the first web space is a common cause of failure in restoration of an opposition. Therefore, deformities or disabilities of the digit must be corrected before or during an opponensplasty procedure to restore the function of the thumb properly. In a case of median nerve paralysis, the only functioning thumb motors are the EPL, EPB, and APL, which result in fixed adduction and external rotational deformity of the thumb. <sup>(17)</sup>

This deformity often can be corrected with physiotherapy and splintage, but if these treatments are unsuccessful, the thumb requires a

dorsal web space incision. Through this incision, the fascia over the AP and the first DI muscles can be released and divided by a subperiosteal stripping of the ulnar side of the first metacarpal. The dorsal web space skin can also be widened with a Z-plasty, skin graft, or flap. In severe contractures, both of the rotational osteotomy at the base of the thumb metacarpal and the trapeziectomy can be required. <sup>(18)</sup>

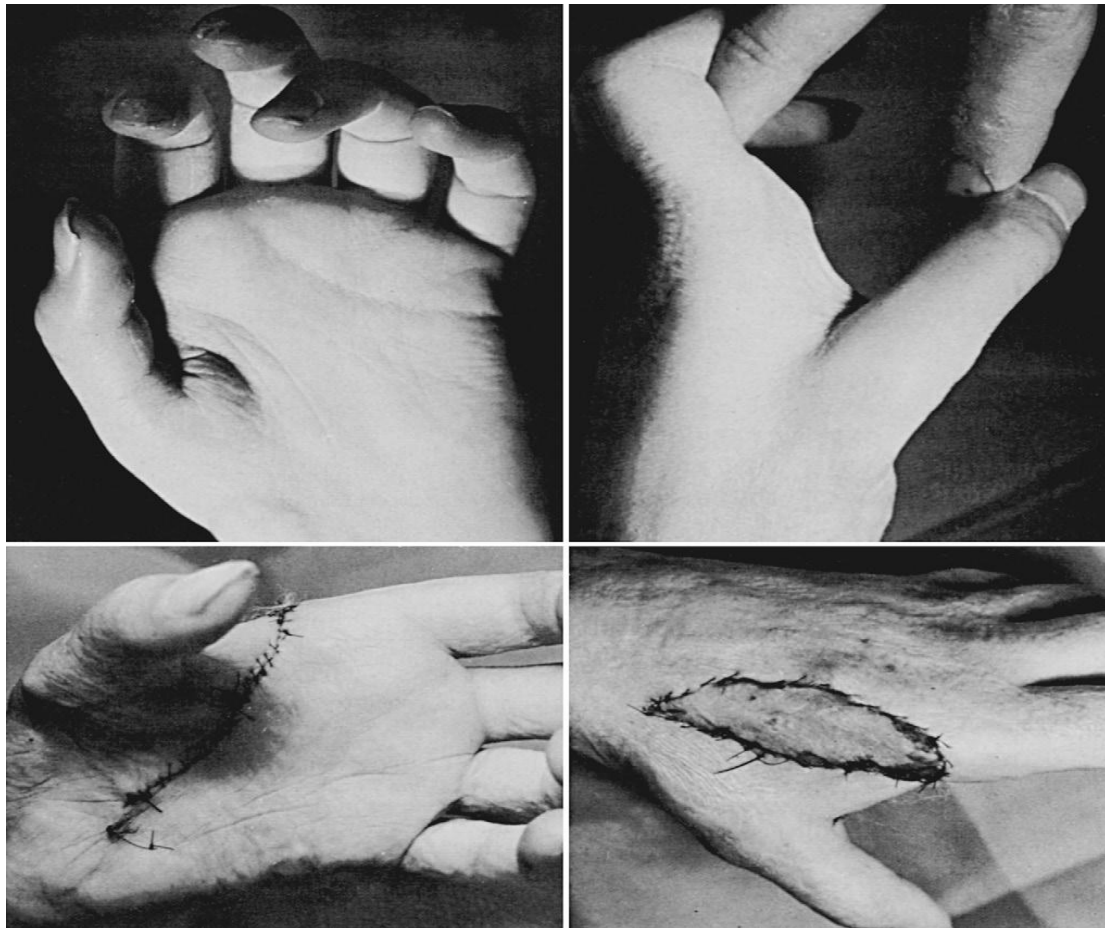For further severe deformity which cannot be corrected by osteotomy, the arthrodesis of the first MCP joint with a 15° of flexion, and slight internal rotation may be indicated. A tendon transfer for opposition still may be useful after such an arthrodesis because the more proximal joints may allow some motion. At the same time, the carpometacarpal joint of the thumb must be freely movable, unrestricted by contracture of the joint capsule or other structures of the thumb web. <sup>(17)</sup>

### **Prevention and Preoperative Treatment of Contractures:**

It is always easier to prevent a soft tissue contracture than to correct an established one. In median nerve palsy and complete thumb intrinsic paralysis, the thumb may adopt a supinated and adducted position, and a first web space contracture may develop. This can usually be readily prevented by passive thumb abduction and opposition exercises, supplemented by abduction splints as needed. Temporary internal splinting of the thumb metacarpal in abduction with a Kirschner wire may be indicated when there is an associated acute, severe thenar or first web space soft tissue injury and thus a high risk of first web space contracture. <sup>(26)</sup>

Established soft tissue contractures must be corrected either before or during opponensplasty, because no opponensplasty has sufficient

strength to improve a preoperative passive loss of opposition. Failure to detect and correct contractures preoperatively is a common cause of failure. First web space contractures are generally due to contractures of the skin and deep fascia on its extensor surface and are usually readily detected. However, contracture of the dorsal capsule of the trapeziometacarpal joint, which restricts opposition but permits abduction, is detected only by careful clinical examination. If supervised physiotherapy and splinting fail to correct a contracture, surgical release is indicated. In the absence of any injury to the thenar muscles or the base of the thumb, first web contractures can usually be released through a dorsal web space incision. The fascia over the adductor pollicis and the first dorsal interosseous muscles is released, and the dorsal web space skin is widened with a skin graft or flap (Figure 11). Isolated capsular contractures of the trapeziometacarpal joint should be released through a small incision over the base of this joint. For severe contractures, both rotational osteotomy at the base of the thumb metacarpal and trapeziectomy have been recommended. An osteotomy modifies rather than improves the range of thumb movement. <sup>(26)</sup>



**Figure 11:** A significant first web space contracture developed after a direct injury to the thenar area and a median nerve laceration. This was released before opponensplasty by using a dorsal rotation flap and skin graft. Postoperatively, the position of the thumb was maintained with a threaded Steinmann pin. <sup>(26)</sup>

### **Donor for Transfer**

The flexor digitorum superficialis (FDS) is likely the most well described and widely used as a donor to achieve the thumb opposition, with numerous variations in techniques of donor harvest, pulley construction, and tendon insertion (Table 1). Among the FDSs, the tendon of the ring finger is primarily selected in most cases, and the second choice is the FDS to the middle finger. The most important point for the selection of the FDS as a donor, however, is that the FDS must be strong enough to restore opposition of the thumb as a transfer and the

flexor digitorum profundus (FDP) in the same digit must be strong enough alone to flex the finger satisfactorily. Therefore, this technique is not indicated in high median nerve lesion or combined median and ulnar nerve lesions. <sup>(17)</sup>

The extensor indicis proprius (EIP) is also an acceptable donor, which is popularly used in high median nerve palsy and other circumstance when the FDS tendons of the ring and middle finger are not available. There is no risk of loss of grip strength, and it does not require the surgical creation of a pulley, as the surgical step that EIP transfer goes around the ulna typically results in a creation of an ideal vector to achieve opposition. <sup>(16)</sup>

The palmaris longus (PL) can be used as a simple transfer of opposition, which is known as Camitz opponensplasty. The PL can be transferred with minimal donor site morbidity in addition to no functional deficit. Furthermore, the PL works synergistically with the APB. The PL transfer is usually performed for restoration of thumb function from the loss of opposition and abduction due to severe thenar atrophy in carpal tunnel syndrome, but the technique is not recommended in the cases with a traumatic median nerve injury. <sup>(19)</sup>

The abductor digiti minimi (ADM), which is a predictably available donor, can be used to restore opposition when other extrinsic donors are not available. The ADM has a similar dimension as the APB, which also can help with cosmesis by restoring some of the bulk of the thenar eminence in severe atrophy or congenital absence of the thenar muscle. <sup>(17)</sup>

The wrist extensors such as extensor carpi ulnaris (ECU) and extensor carpi radialis longus (ECRL) with a free tendon interposition

graft are also used as the next choices, but it should be considered only if the other wrist extensors are strong and have not been or will not be transferred elsewhere. The EDM is rarely selected because its strength is not enough to restore thumb opposition, and it requires tendon grafting to reach the point of attachment on the thumb .<sup>(17)</sup>

**Table 1:** Satisfaction rate of opponensplasty.<sup>(17)</sup>

Transferred tendon	Satisfaction rate	Reported studies
EIP	88%	Anderson et al. <sup>(29)</sup>
	88%	Burkhalter et al. <sup>(30)</sup>
FDS	75%	Kraker et al. <sup>(31)</sup>
	78%	Jacobs and Thompson. <sup>(32)</sup>
	81%	Jensen. <sup>(33)</sup>
Palmaris longus	93%	Terrono et al. <sup>(34)</sup>
	91%	Foucher et al. <sup>(35)</sup>
	85%	Park et al. <sup>(36)</sup>
ADM	80%	Wissinger and Singsen <sup>(37)</sup>

**Preoperative assessment:**

Selecting the optimum treatment for the patient with paralysis of the thenar intrinsic muscles depends on a variety of factors that include the cause of the paralysis, the duration and severity of the functional impairment, and any other significant medical problems. Congenital aplasia or hypoplasia of the thenar muscles is obviously a very different problem than paralysis of those muscles following a median nerve laceration when there are also profound sensory deficits on the tactile surfaces of the thumb, index finger, and middle finger. When intrinsic



muscle paralysis is the result of a nerve laceration, a neurorrhaphy is preferable to a tendon transfer, provided that the procedure is performed within a time frame that permits muscle reinnervation. Motor end plates of denervated muscles undergo fibrosis at approximately 18 months. Therefore, regenerating motor axons must reach those end plates before that time. A median nerve repair at the wrist has a better prognosis for reinnervating paralyzed intrinsic muscles than a similar injury in the elbow or in the proximal forearm because the regenerating axons have a shorter distance to travel. Using the generally accepted guide that regenerating motor axons progress at the rate of 1mm/day or 25mm(1 inch) a month, a reasonable estimate can be made for the time that muscle reinnervation can be expected and if it will be within the 18-month time frame. For chronic injuries, the time that has lapsed from the date of the original injury is added to the distance the regenerating axons must travel when deciding if a neurorrhaphy would be the appropriate treatment option. It would be the appropriate option for a nerve injury at the wrist that is 6 months old, but it would not be appropriate for an injury that is 18 months old, because by the time the regenerating motor axons reached the intrinsic muscles, the end plates would likely be fibrotic. The prognosis for muscle reinnervation is also dependent on the type of injury. A neurorrhaphy for a sharp lacerating injury generally has a better prognosis than for a ripping injury caused by a power saw or for a high-velocity injury, such as a gunshot wound, because both types of injuries result in large zones of nerve damage, and repair usually requires an interposition nerve graft. .<sup>(15)</sup>

The extent of the functional deficit in the patient with thenar muscle paralysis must be carefully evaluated before deciding on a course of treatment or whether any treatment is needed. Frequently, when the

paralysis is secondary to a median nerve injury, the sensory deficit is far more disabling than the motor deficit. This is especially true in those patients who can still abduct their thumbs through the action of the radial head of the FPB, which frequently has a dual innervation from both median and ulnar nerves.<sup>4</sup> Although these patients are unable to position their thumbs in complete opposition, the abduction component of opposition is usually sufficient and there is no need for an opposition tendon transfer. However, when there is significant functional impairment and an opposition tendon transfer is warranted, it is important to evaluate the activities of that particular patient to determine the optimum type of transfer. <sup>(15)</sup>

Before any tendon transfer, preoperative passive mobility of the thumb should be complete or almost complete; passive abduction is more important than passive rotation. An adduction contracture of the first web space must first be corrected and this can often be accomplished with nonoperative measures that involve passive abduction thumb exercises. To be effective, the patient should do the exercises frequently for brief periods, generally 10 repetitions every hour or even every half hour during the day. It is also important that the exercises are performed properly with the patient applying an abduction force to the ulnar side of the head of the metacarpal and not to the ulnar side of the proximal phalanx, which can result in stretching of the ulnar collateral ligament of the MP joint and lead to instability. Supervised therapy with a hand therapist is usually beneficial. Those treatments are an adjunct and not a substitute for the patient's own exercises. A static C-shaped splint for the thumb web space is used when the patient is not exercising. A dynamic abduction splint is also effective and is generally worn for 20 to 30 minutes several times during the day. As with passive abduction

exercises, the forces applied by static and dynamic abduction splints must be against the ulnar side of the metacarpal head and not against the ulnar side of the phalanx to avoid causing instability of the MP joint. When nonoperative measures are unsuccessful, surgery is necessary and precedes the tendon transfer. <sup>(15)</sup>

### **Surgical procedures:**

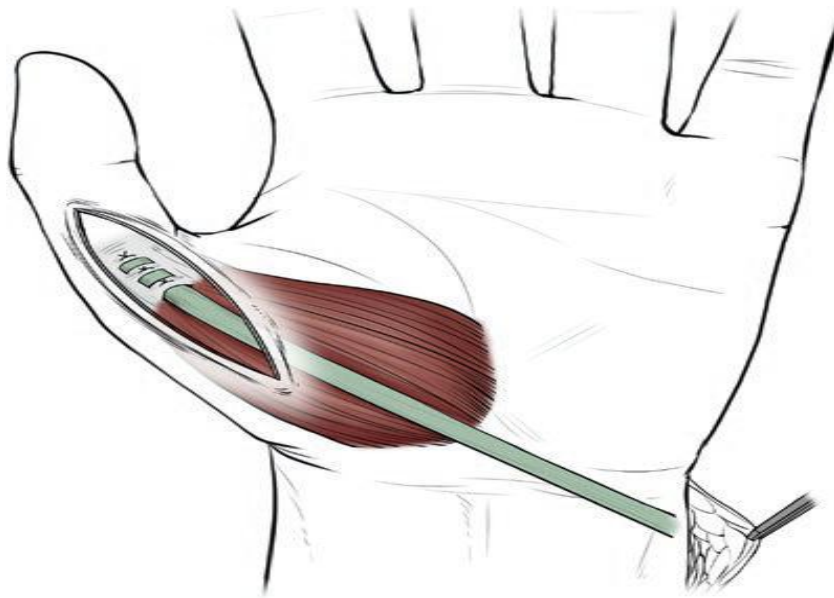
As with all tendon transfer surgery, appropriate patient selection is paramount to an acceptable outcome. First and foremost, the patient must be clearly counseled about the nature of the surgery and the importance and general timeline of postoperative recovery and rehabilitation. Reasonable expectations for the outcome should be shared by the surgeon and patient, and the patient's willingness and ability to comply with postoperative instructions, including supervised hand therapy, should be ascertained. Soft tissue equilibrium should be achieved before considering tendon transfers. To ensure an optimum setting for success, all articulations of the thumb should be supple to allow for effective excursion and effect of the transferred tendons. This often requires a period of regular and dedicated home exercises, supplemented by supervised hand therapy. Any adduction contracture must be corrected, and this can be assisted by a thermoplast first web "spacer" fashioned by the hand therapist. Available donors should be meticulously assessed, particularly in the setting of combined nerve injuries and relevant musculoskeletal trauma. For example, a combined median/ulnar nerve palsy, or multiple tendon lacerations of the wrist or forearm, may preclude the use of specific donors. The MCP joint of the thumb should be stable and significant laxity, particularly of the ulnar collateral ligament, can be addressed by joint arthrodesis. <sup>(16)</sup>

### **Extensor indicis proprius (EIP) transfer**

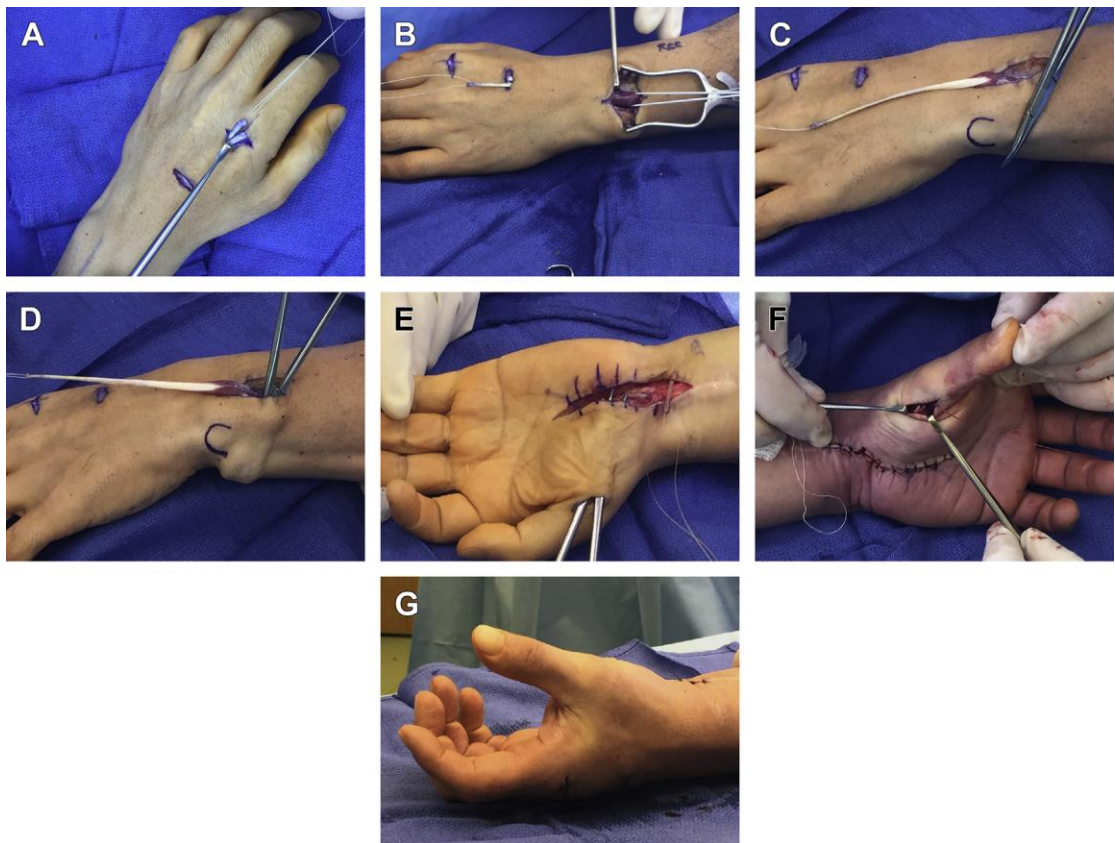
It should be kept in mind that anatomic variance of the EIP includes its congenital absence at this level in 0–4%, radial location relative to extensor digitorum communis (EDC) in 10%, and multiple slips in 3–14% of humans or cadaveric specimens ( figure 12) .<sup>(20)</sup>

A dorsal transverse incision is made proximal to the MCP joint of the index finger, and the EIP is identified just ulnar and deep to the extensor digitorum superficialis to the index finger. The EIP is transected just proximal to the sagittal bands, and the remnant distal stump is sutured to the intact EDC to assist an even distribution of extensor strength across the MCP joint. Another incision is made proximal to the extensor retinaculum of the 4<sup>th</sup> compartment, where the musculotendinous junction of the EIP is identified. After the fascial attachments around the EIP are divided, the EIP is pulled proximally and withdrawn from this incision. Next, an oblique incision is made just proximal to the pisiform and distal forearm around the ulnar neck. And then the EIP is transferred to this incision through a subcutaneous tunnel. At this point, special care should be taken to avoid an iatrogenic injury to the dorsal cutaneous branch of the ulnar nerve. Next, a small incision is made on the dorsoradial aspect of the thumb MCP joint to expose the APB insertion. And the EIP is then subcutaneously passed over the ulna and the transverse carpal tunnel ligament and reached to the thumb MCP while ensuring that the tendon goes superficially to the FCU tendon. At this point, the ulna acts as a functional pulley for this tendon transfer. The transfer tendon is subsequently sutured into the APB insertion, with an appropriate tensioning that results in the thumb in maximal opposition with the wrist in 30° flexion.<sup>(21)</sup>

Postoperatively, a thumb Spica splint is applied for 4 weeks with the thumb and wrist held in a neutral position. The active assisted range of motion exercises starts at 4 weeks after surgery, and the resistive pinch and grip exercises start at 8–10 weeks. All activities except those that are requiring high demand can be allowed at 3–4 months. <sup>(17)</sup>



**Figure 12:** Extensor indicis proprius is delivered into a dorsoulnar wrist incision and passed through a subcutaneous tunnel around the wrist to an incision over the thumb metacarpophalangeal joint, and then it is sutured to the abductor pollicis brevis tendon. <sup>(17)</sup>



**Figure 13:** EIP opponensplasty. (A) A dorsal transverse incision is made just proximal to the MCP joint of the index finger, and the EIP is identified just ulnar and deep to the EDC. It is transected just proximal to the sagittal bands. (B, C) Identification of the EIP musculotendinous junction through an incision made over fourth extensor compartment. Fascial attachments are divided and the EIP is pulled proximally into this incision. As in this patient, occasionally the EIP will not glide smoothly between these 2 incisions, and a counter incision over the dorsal radial mid hand should be used to identify and divide any persistent fascial attachments. (D) A subcutaneous tunnel is developed around the ulna, and (E) also between the pisiform and the insertion site over the radial border of the thumb MCP. In the setting of a concurrent carpal tunnel release, as in this patient, an extensile carpal tunnel incision replaces the need for an incision just proximal to the pisiform. The EIP is passed subcutaneously around the ulna, into the carpal tunnel incision, then to the incision at the radial border of the thumb. (F) The tendon is sutured into place. (G) Appropriate tensioning results in the thumb resting palmarly abducted and opposite the index and middle fingers with the wrist at neutral.<sup>(16)</sup>

### **Flexor digitorum superficialis (FDS) transfer**

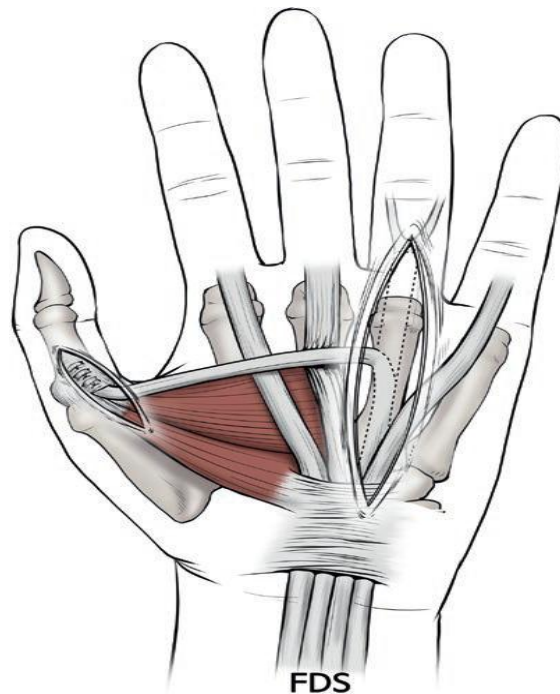
The FDS is harvested through a 3–4 cm longitudinal incision on the radial border of the hypothenar muscle, which is overlying the A1 pulley of the ring or middle finger. Once the FDS is isolated, the proximal traction on the FDS typically with full flexion of the finger allows for the subsequent visualization of the bifurcation of FDS near to the Campers chiasm, and the FDS is transected at this level. At this point, I do not recommend transecting near its insertion into the middle phalanx, because this technique has potential drawbacks, including the risk of devascularization of the vincular system in the FDS and the distinct possibility of the development of a swan neck deformity (Figure13).<sup>(22)</sup>

Once the donor FDS has been harvested distally, there are two options with regard to pulley formation: Royle-Thompson opponensplasty and Bunnell's opponensplasty. The Royle-Thompson procedure includes rerouting the FDS around the ulnar border of the palmar aponeurosis and transferring the FDS subcutaneously to the thumb. But this is not a favorite procedure to utilize, because the pulley is not fixed and migrated proximally.<sup>(21)</sup>

Above all, a more crucial problem is that the vector of pull created with this technique is more suited to restore thumb flexion and abduction rather than the true opposition. The Bunnell's opponensplasty originally included looping a free tendon graft around the FCU tendon as a pulley, which was thus designed for the restoration of full thumb opposition with running the transfer in line with the APB fiber. However, the problem of this original technique is that raw surface of the pulley encourages adhesion formation and radial migration of this pulley. To prevent this critical problem in performing the procedure, a modified technique of

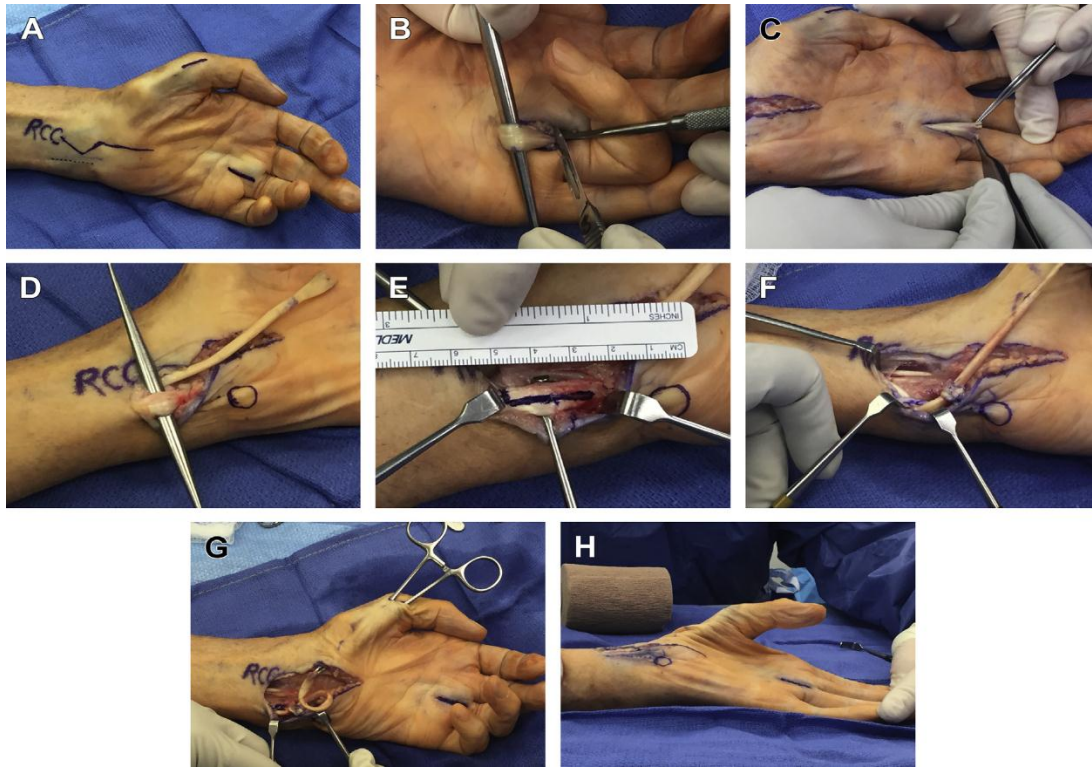
attaching the distally based slip of FCU tendon to the ECU tendon is preferred for pulley reconstruction. However, a great care should be taken during creating this pulley, as the ulnar neurovascular bundle lies in very close to the FCU. <sup>(22)</sup>

The next steps is subcutaneous passage of a transferred FDS tendon to the thumb MCP joint, requiring a fairly aggressive blunt spreading, which is because the deep skin layer of the proximal palm is intimate with the palmar fascia. Finally, the tensioning of the transfer must be set as a passive wrist extension, which results in full thumb opposition. The patient should be informed that a potential loss of grip strength, particularly with use of the ring finger FDS, could result from the pursuing of the procedure. <sup>(17)</sup>



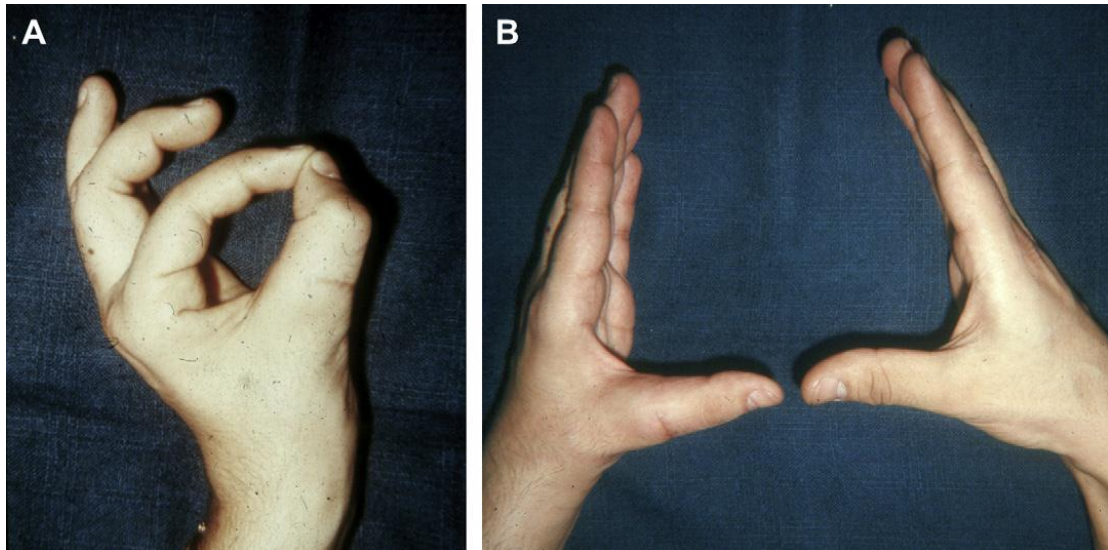
**Figure 14:** The window in the palmar fascia overlying the neck of the third metacarpal is used as a pulley, and the flexor digitorum superficialis transfer is attached to the abductor tubercle of the thumb. <sup>(17)</sup>





**Figure 15:** FDS opponensplasty in an 87-year-old man with combined end-stage carpal tunnel syndrome, profound thenar atrophy, and ulnar neuropathy, absent palmaris, with intact ring finger FDS/FDP on preoperative examination. (A) The FDS is harvested through an incision over the ring finger A1 pulley. (B, C) Once the FDS is isolated, the finger is fully flexed, proximal traction on the FDS typically allows for visualization of the bifurcation of FDS at Camper chiasm, and the FDS is transected. A several-centimeter incision can be made over the most distal aspect of the FCU (A, dotted line). (D) In this setting of a concurrent carpal tunnel release, both the proximal FDS and FCU can be accessed through an extensile carpal tunnel incision in lieu of a separate incision directly over the FCU. (E, F) A loop pulley is created in the FCU by transecting the radial one-half of a split approximately 5 cm proximal to the pisiform, and suturing this radial slip to the intact ulnar half of the FCU distally. The FDS is passed around the ulnar intact half and then through the loop. (G) The tendon is then passed through a subcutaneous tunnel to the radial aspect of the thumb MCP, where a third incision is made and the FDS is either inserted into the ulnar base of the proximal phalanx or directly attached to the APB tendon. (H) The transfer is tensioned such that passive wrist extension will result in full thumb opposition.

(16)



**Figure 16:** Postoperative results FDS opponensplasty. (A) Complete opposition restored. (B) Comparative photo with the right hand showing equal pronation of both thumbs. <sup>(15)</sup>

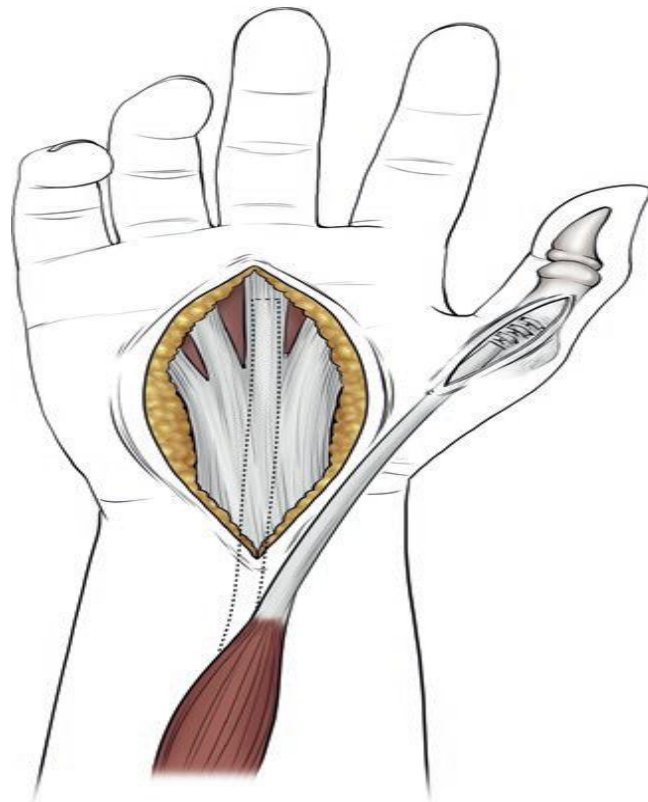
### **Palmaris longus (PL) transfer (Camitz opponensplasty)**

Before proceeding with this surgery, it should be confirmed whether the patients have a PL or not, because 15–20% of humans do not have the tendon. <sup>(23)</sup>

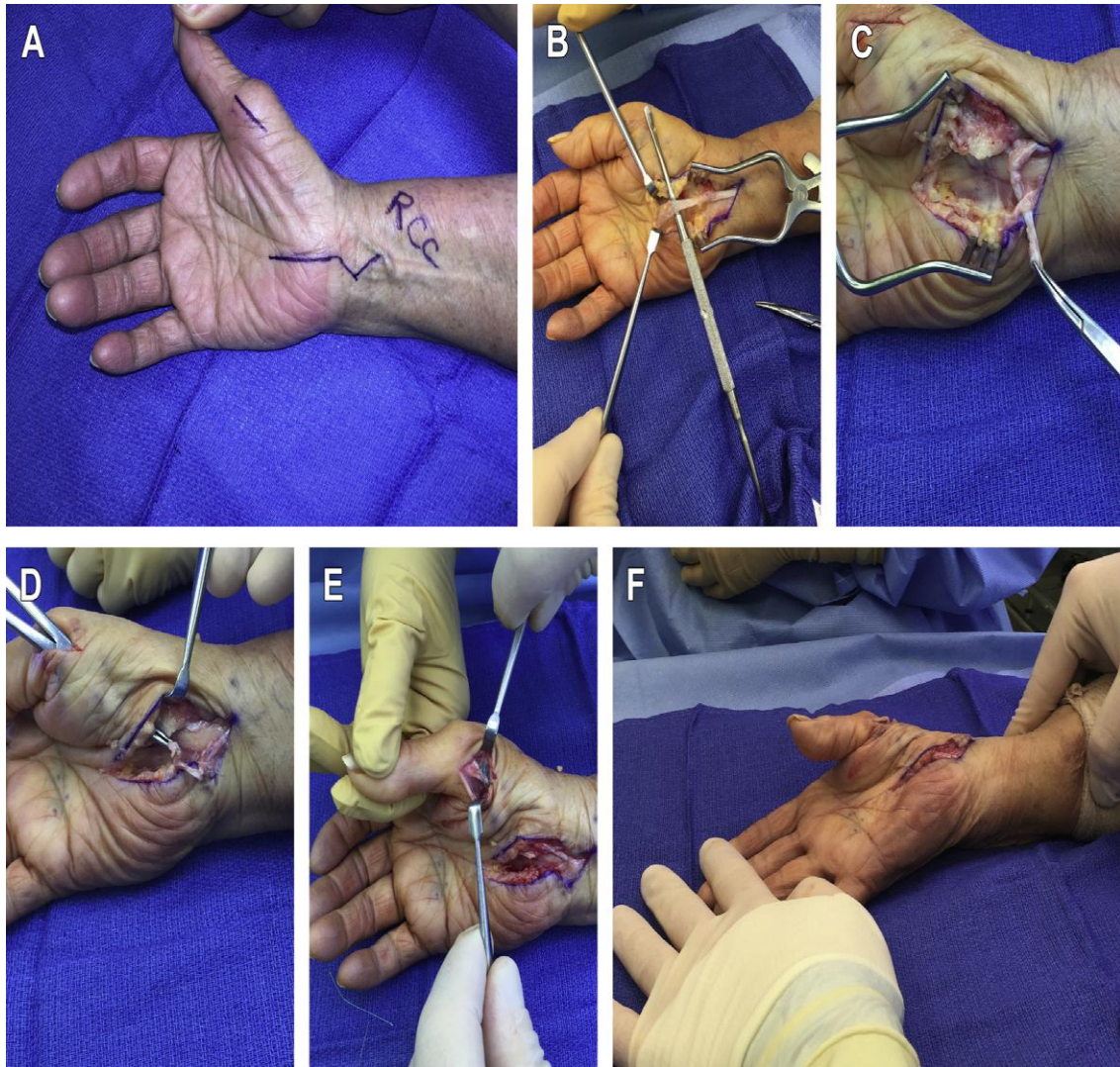A skin incision is made starting with 2 cm proximal to the distal wrist crease with a zigzag fashion, running in line with the ring finger, and extending distally to the distal palmar crease. Since the PL is continuous distally with the pretendinous bands of the palmar aponeurosis, the PL can be free up enough length to reach the thumb, with a 1.0–1.5-cm-wide strip in continuity with the tendon. After an incision over the dorsoradial aspect of the thumb MCP joint is made, a subcutaneous tunnel is then created from an incision at the distal forearm incision to this incision. At this point, the palmar cutaneous branch of the median nerve, which runs radial to the PL and in the radial floor of the flexor carpi radialis sheath, must be preserved during the procedure. The transferred PL is then sutured to the APB tendon with the thumb placed

in passively full abduction while the wrist is held in a neutral position. (Figure 16).<sup>(24)</sup>

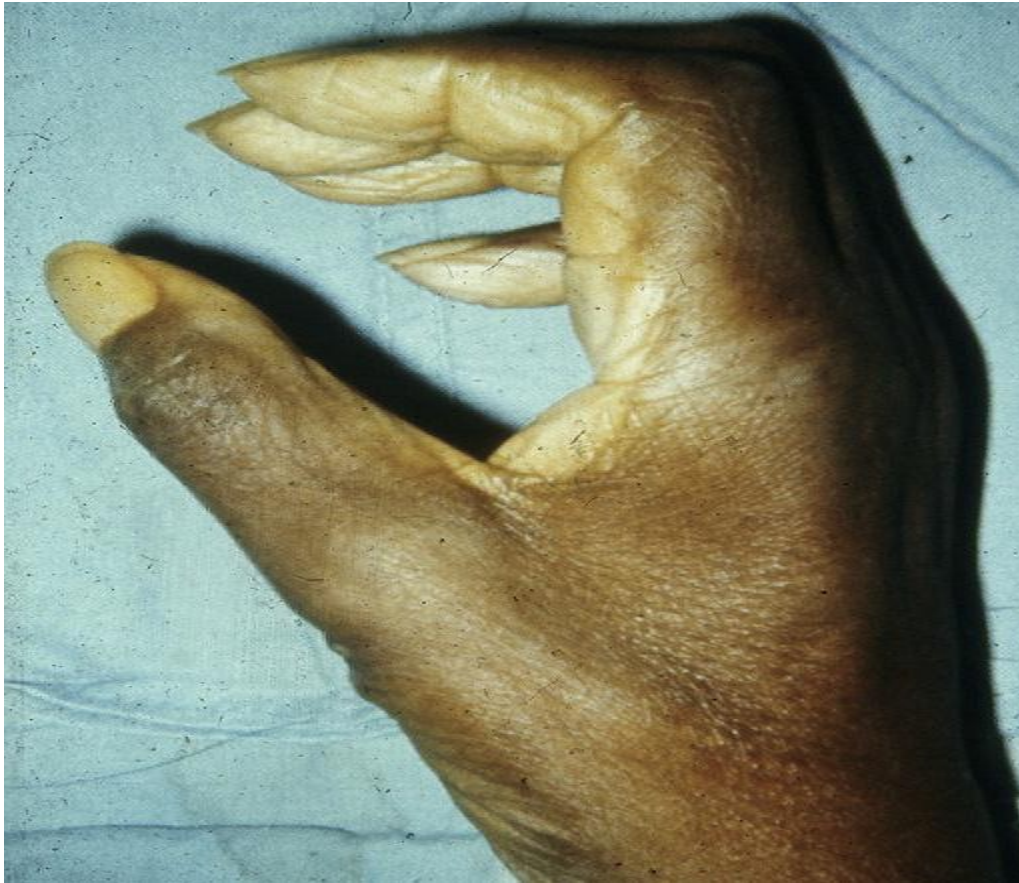Several variations of a modified Camitz procedure, which is focusing on the incorporation and placement of a pulley, have been recently published. Kang and colleagues reported modified Camitz opponensplasty creating a transverse carpal ligament loop pulley in advanced carpal tunnel syndrome with good outcomes. However, there has been some debate about the necessity of performing a PL opponensplasty with the case of carpal tunnel syndrome, as a gradual recovery of thenar atrophy has been commonly noted after carpal tunnel release.<sup>(24)</sup>



**Figure 17:** The palmaris longus is detached with a strip of palmar aponeurosis and attached to the abductor pollicis brevis insertion.<sup>(17)</sup>



**Figure 18:** PL opponensplasty (Camitz transfer) in an 81-year-old man with end-stage carpal tunnel syndrome and profound thenar atrophy. (A) An extensile carpal tunnel incision is made. (B) The PL is elongated with a 1.0-cm-wide to 1.5-cm-wide strip of palmar fascia. (C–E) A generous subcutaneous tunnel is then created between the distal forearm and the dorsoradial aspect of the thumb MCP joint, and an incision is made overlying the APB insertion, taking care to preserve the branch’s radial sensory nerve. (C) The PL can be passed through a slit in the ulnar leaf of the release transverse carpal ligament to effect an appropriate pulley. (E, F) The fascial extension is then sutured to the APB tendon with the thumb placed in full passive abduction while the wrist is held neutral.<sup>(16)</sup>

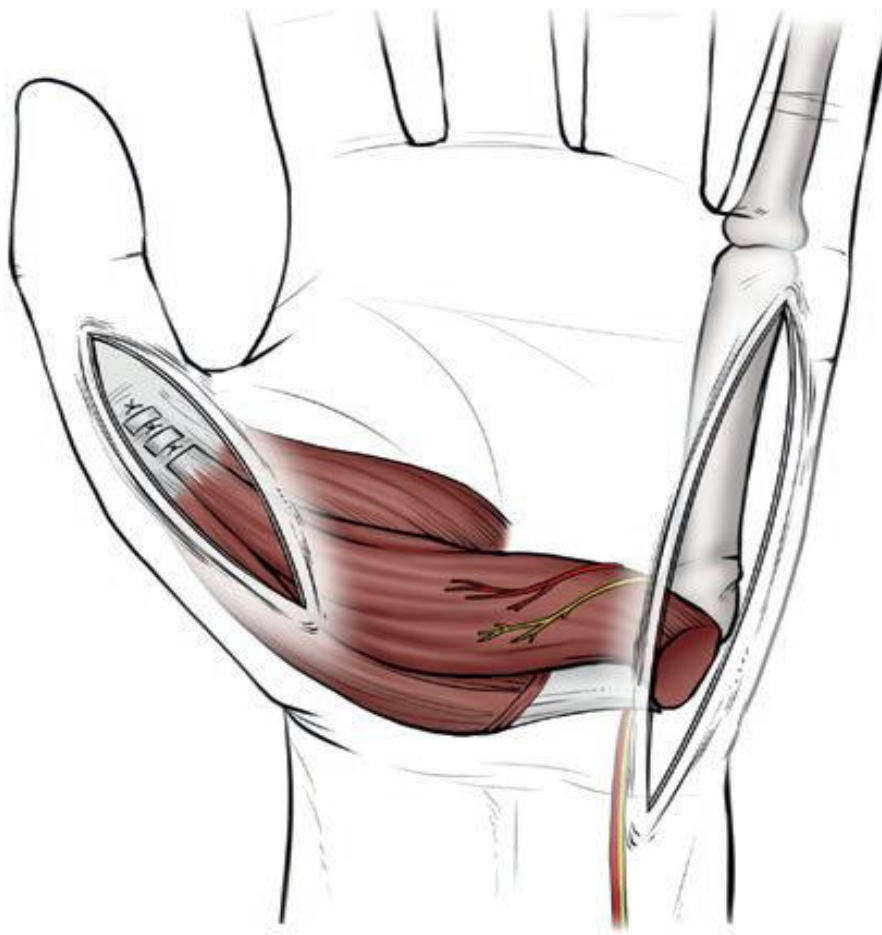


**Figure19:** Postoperative PL opponensplasty thumb abduction was restored; even some pronation was restored. <sup>(15)</sup>

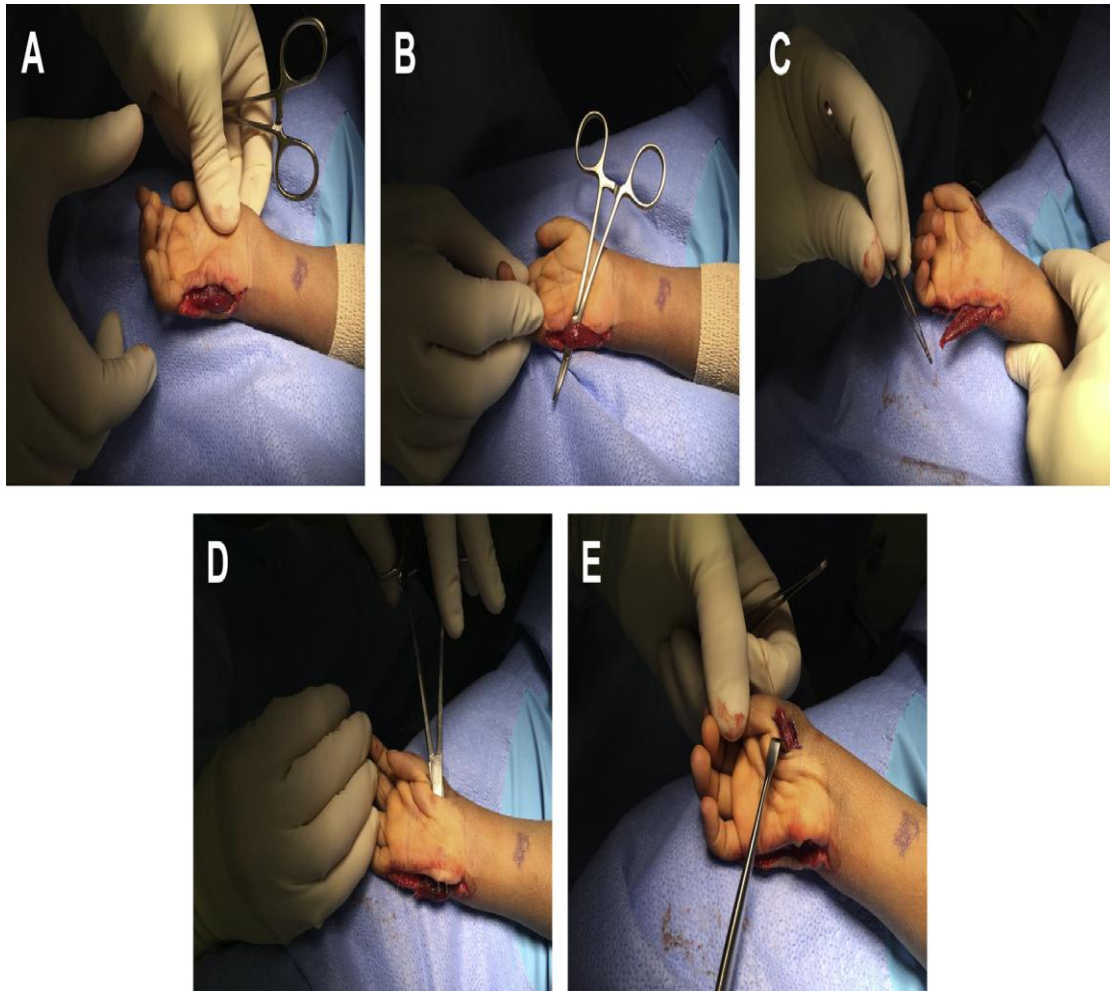
### **Abductor digiti minimi (ADM) transfer (Huber opponensplasty)**

A midlateral incision is made on the ulnar border of the little finger and extended to a point just proximal to the pisiform. The insertion of the ADM into the proximal phalanx and extensor mechanism is meticulously incised, therefore maintaining as much length of the tendinous insertion as possible, ensuring an adequate length to reach the insertion site. And ADM is then meticulously separated from radially adjacent flexor digiti minimi and freed up from its originations including the pisiform, pisohamate ligament, and FCU, with a great care to preserve the neurovascular pedicle, which locates dorsoradially and just several millimeters distal from the pisiform (Figure 19). <sup>(25)</sup>

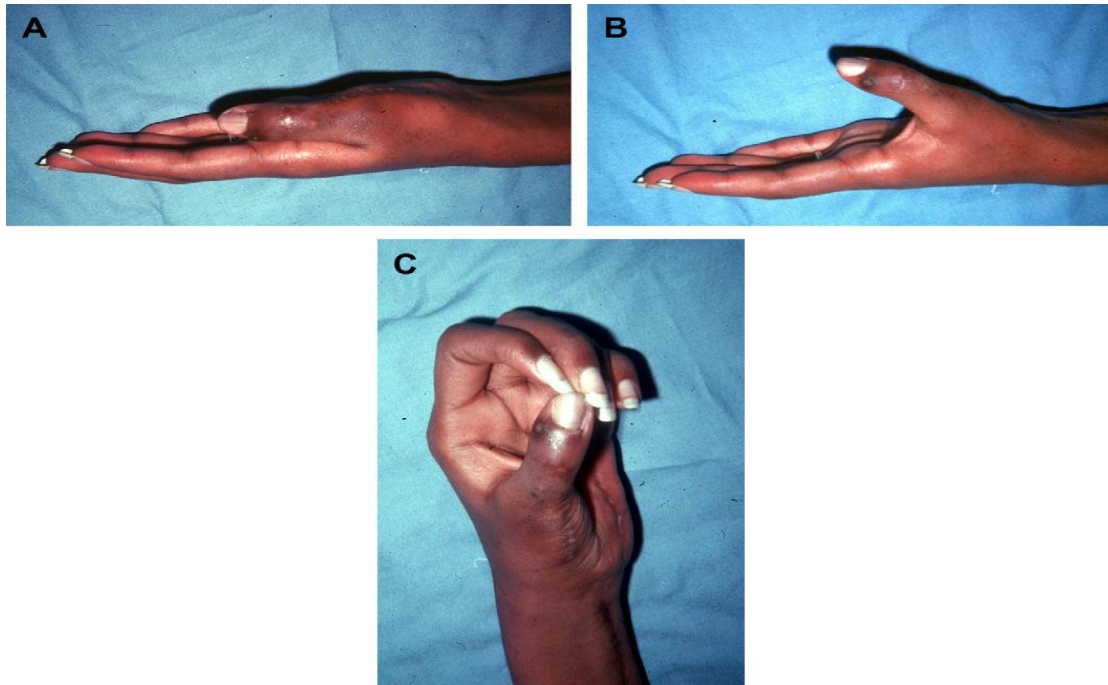
After a generous subcutaneous tunnel is created toward a second incision made over the APB insertion into the thumb, the ADM is subsequently passed through the tunnel. This step requires a turn through 180° on its longitudinal axis to reduce tension on neurovascular bundle supplying the ADM. Next, the thumb is placed in maximum opposition and the ADM is sutured appropriately. In some cases with an inadequate length, the transfer requires an augmentation with a free tendon interposition graft. <sup>(17)</sup>



**Figure 20:** Abductor digiti minimi is detached with neurovascular structures while preserving an attachment to the flexor carpi ulnaris. The abductor digiti minimi is rotated on its long axis and passed subcutaneously and attached to the adductor pollicis brevis. <sup>(17)</sup>



**Figure 21 :** ADM opponensplasty in a 2-year-old with hypoplastic thumb. (A, B) An incision is designed extending from the ulnar base of the small finger to a point just proximal to the pisiform, exposing the entire broad muscle belly of the ADM. (C) The ADM insertion into the proximal phalanx and extensor mechanism is incised. (D) A generous subcutaneous tunnel is created toward a second incision made over the APB insertion of the thumb, and (E) the ADM is passed through the tunnel. <sup>(16)</sup>



**Figure 22:** Postoperative results ADM opponensplasty. (A) No loss of adduction. (B) Full abduction restored. (C) Complete opposition. <sup>(15)</sup>

### **Postoperative Management of Opponensplasty**

The thumb is immobilized in opposition for 3 weeks after most opponensplasties, and the wrist should also be immobilized if the tendon transfer crosses the flexor surface of this joint. Transfers of muscles with relatively short excursions, such as the EIP, should be relaxed by immobilizing the wrist in 30 degrees of flexion and the thumb in full opposition. However, after transfer of muscles with larger excursions, such as the superficialis, the wrist can be immobilized in neutral with the thumb in full opposition. If the transfer is attached to either the extensor mechanism or the APB insertion, the IP joint of the thumb should probably be immobilized in full extension. Some find it useful to maintain thumb opposition postoperatively by using cyanoacrylate glue to stick the skin of the thumb tip to the little finger at the end of the operation, before the transfer's tension is set. With desquamation, the



thumb is spontaneously released from the little finger after 2 to 3 weeks. After 3 weeks, all splints can usually be discarded, and most patients quickly regain thumb control. The emphasis should be on early restoration of wrist movement, which will alternately relax and tighten the opponensplasty. <sup>(26)</sup>

In certain conditions, such as high combined median and ulnar nerve palsies and diseases such as Charcot-Marie-Tooth disease and leprosy, the thumb extensors are strong and unbalanced and the sensory loss is profound. In these conditions the patient may stretch the transfer if the thumb is mobilized after 3 weeks, and it is advisable to protect the opponensplasty for 3 months with splints that prevent full adduction, supination, and extension of the thumb. <sup>(26)</sup>

### **Complications of low Tendon transfer:**

Donor tendons are attached to recipient tendons most commonly using the Pulvertaft weave. Utilizing this method, the donor tendon is woven back and forth through the substance of the recipient's tendon with each pass 90 degrees perpendicular to the previous pass and fixed to the tendon using a mattress suture of 2-0 or 3-0 ticon or fiberwire depending on surgeon preference and the size of the tendon. A minimum of three passes should be used for appropriate strength. <sup>(27)</sup>

Complications are related mainly to an improper initial graft tensioning and repair site rupture or loosening as a result of slit propagation or knot failure. Alternative repair techniques (spiral linking and loop-tendon suture) can be used based on surgeon preference to help improve the biomechanical strength of the repair site with the tradeoff of increased bulk of the repair. <sup>(27)</sup>

## **PATIENTS AND METHODS**

This is a Prospective randomized study includes 30 cases of chronic low median nerve injury with lost opposition in patients presenting to Behna University Hospital in the period between December 2019 to April 2021.

### **Inclusion criteria:**

One or more of the following

1. Consecutive patients have evidence of low median nerve injury
2. Isolated median nerve injury
3. Traumatic nerve injury more than one year
4. Associated with inefficiency in daily activities

### **Exclusion criteria:**

Any cases with the following criteria will be excluded

1. Incomplete documentation
2. Unavailable healthy tendon for transfer
3. Injury less than one year
4. Neuropathic condition as leprosy
5. Anticipated poor co-operation of the patient
6. Combined nerve injury

**Demographic features:**

• **Sex incidence:**

There were 19 males and 11 females.

**Age incidence:**

The age of the patients ranged from 18 to 40 years.

**Mechanism of Injury:**

Out of 30 cases: 20 patients were due to trauma, 5 were due to Iatrogenic and 5 were due to self-injury.

**Side of injury:**

Out of the 30 patients, there were 22 right sided and 8 left sided.

**Patient evaluation:**

**Patient's history:**

- Clinical history was taken from the patient in the sort of name, sex, age, job, address and smoking habits.
- Associated illness like diabetes, hypertension and cardiac condition.
- Patients were asked about the mechanism of injury and if there is any associated injuries.

**Clinical examination:**

Standard hand examination was performed in the form of:

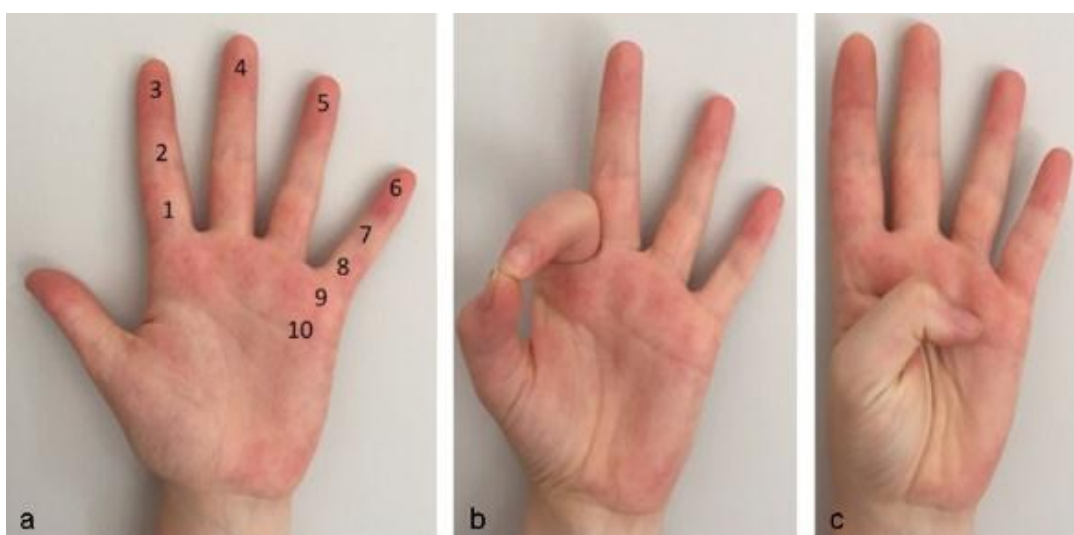
1. Tenderness
2. Swelling
3. Range of motion of hand
4. Skin condition
5. Neurovascular examination

Also examination of associated injuries was performed.

**Opposition evaluation:**

1. Assessment of opposition by Kapandji score and assessment of degree of pain by VAS and hand grip by QuickDASH score.
2. All the patients will have nerve conduction and electromyogram.

We used the **Kapandji score** used to measure opposition of the thumb (/10). The contact between the top of the thumb pulp and the other fingers is used to calculate this score (figure 22).<sup>(39)</sup>



**Figure 23:** Kapandji score. (a) Numbered fingers to establish the opposition score. (b) The thumb touches only the middle phalanx of the index, Kapandji score is 2. (c) The thumb touches the distal palmar flexion creases, Kapandji score is 10.<sup>(39)</sup>

We used the **visual analog scale (VAS)** is a pain rating scale first used by Hayes and Patterson in 1921. Scores are based on self-reported measures of symptoms that are recorded with a single handwritten mark placed at one point along the length of a 10-cm line that represents a continuum between the two ends of the scale—“no pain” on the left end (0 cm) of the scale and the “worst pain” on the right end of the scale (10 cm). Measurements from the starting point (left end) of the scale to the

patients' marks are recorded in centimeters and are interpreted as their pain. <sup>(40)</sup>

We used the Quick Disabilities of the Arm, Shoulder, and Hand (**QuickDASH**) score (in which a score of 0 means no disability and a score of 100 means complete disability). <sup>(41)</sup>

**Surgical Technique:**

**Fitness to surgery:**

The patients were assessed for fitness for surgery by clinical history, examination and routine pre-operative laboratory investigations.

**Consent:**

Standard consent was taken from the patients

**Surgical procedure:**

▪ **Anesthesia:**

Patients were anaesthetized by general anaesthesia or brachial block.

▪ **Position:**

Patients were operated on a standard orthopedic table, in supine position.

The patient was placed supine given intravenous antibiotic The FDS of the ring finger is harvested through an incision overlying the A1 pulley of the ring finger. Once the FDS is isolated, the finger is fully flexed, proximal traction on the FDS allows for visualization of the bifurcation of FDS, and the FDS is transected at this level concurrent incision at carpal tunnel. The FDS is then passed through a subcutaneous tunnel to the

radial aspect of the thumb MCP, where a third incision is made and the FDS is either inserted into the ulnar base of the proximal phalanx or directly attached to the APB tendon. The transfer is tensioned such that passive wrist extension will result in full thumb opposition. Then suturing the skin and slap is done.

### **Postoperative Care**

The patients receive intravenous antibiotics for at least 48 hours, pain medication as required discharging after 24 hours

### **Follow-up care**

Clinically examination after 2 weeks and removal of the skin suture then at 4 weeks removal of the slap and allow for controlled range of motion, and at 3, 4 months postoperatively

### **Assessment and final outcome evaluation**

The patient's data will include time of injury and time of presentation and range of motion of thumb and assessment of opposition by Kapandji score and assessment of degree of pain by VAS and hand grip measurement and assessment using QuickDASH score.

### **Statistical analysis**

Data management and statistical analysis were done using SPSS version 25. (IBM, Armonk, New York, United States). Normality of numerical data was assessed using Shapiro-Wilk test and direct visualization methods. Then, numerical data were summarized as means and standard deviations or medians and ranges. Categorical data was summarized as numbers and percentages. Kapandji and VAS scores were compared prior to surgery, at 3 months, and at 6 months using Friedman's test, while QuickDash score was compared using repeated measures ANOVA. Post-hoc analysis was done using Bonferroni method. All P values were two sided. P values less than 0.05 were considered significant.

## Results

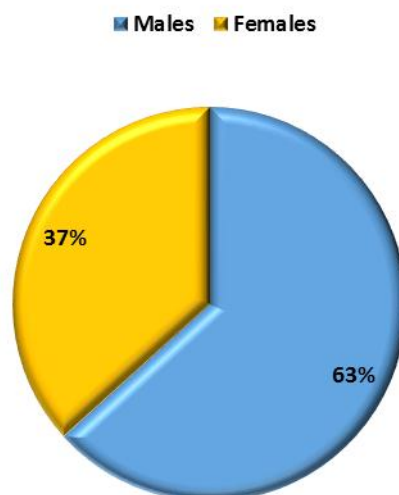
This prospective study was done in Benha university hospitals, Orthopedic Department, on thirty cases of chronic low median nerve injury with lost opposition.

### ❖ **Demographic characteristics of the studied patients**

- The mean age of the studied patients was 29 years, with a standard deviation of 11 years. Regarding gender, 63.3% were males, and 36.7% were females.

**Table (2)** Demographic characteristics of the studied patients

<i>Demographics</i>		
<b>Age (years)</b>	Mean $\pm$ SD	29 $\pm$ 11
<b>Gender</b>	Males n (%)	19 (63.3)
	Females n (%)	11 (36.7)



**Figure (24)** Gender distribution of the studied patients

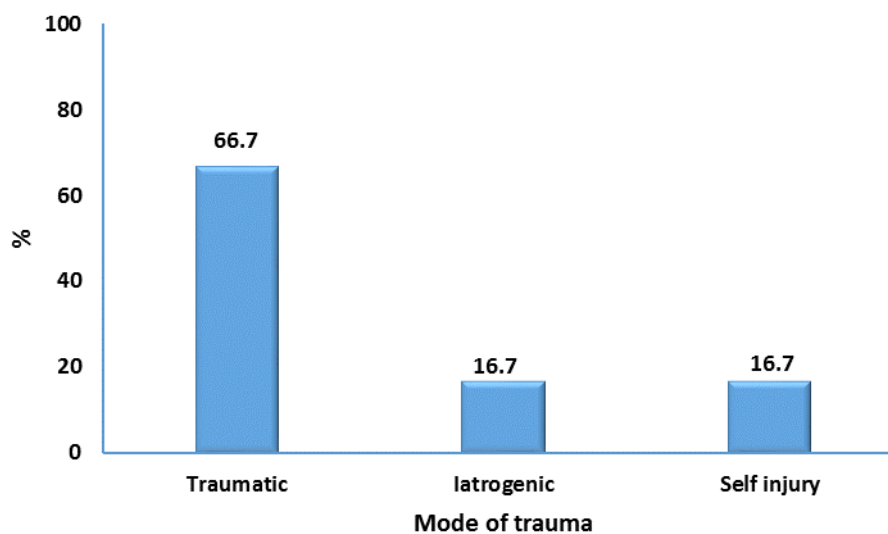


❖ **Mode of injury in the studied patients**

- The most frequent mode of injury was traumatic (66.7%), followed by iatrogenic and self-injuries (16.7% for each).

**Table (3)** Mode of injury in the studied patients

		<b>n (%)</b>
<b>Mode of injury</b>	Iatrogenic	5 (16.7)
	Self-injury	5 (16.7)
	Traumatic	20 (66.7)



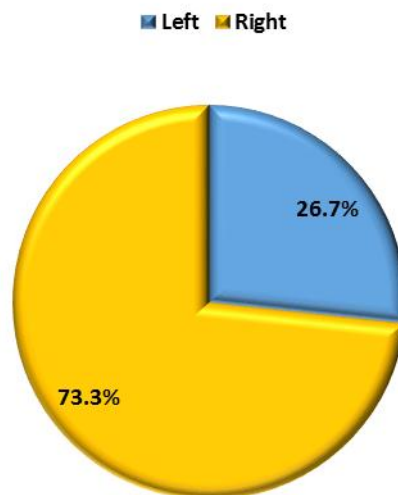
**Figure (25)** Mode of injury in the studied patients

❖ **Injured hand laterality in the studied patients**

- Regarding laterality of injured hand, more than two thirds of patients had right hand injury, and 26.7% had left hand injury.

**Table (4)** Laterality of injured hand in the studied patients

		n (%)
Injured hand	Left	8 (26.7)
	Right	22 (73.3)



**Figure (26)** Laterality of injured hand in the studied patients

❖ **Time to surgery in the studied patients**

- The mean time between injuries to surgery was 17 months, with a standard deviation of 3 months.

**Table (5)** Injury to surgery time in the studied patients

	Mean $\pm$ SD
Time between injury to surgery (months)	17 $\pm$ 3

❖ **Kapandji score before surgery, after 3 months and 6 months in the studied patients**

- There was an overall significant difference between Kapandji score before surgery, after 3 months, and after 6 months, P value was  $<0.001$ . Post-hoc analysis revealed that median Kapandji score was significantly lower before surgery (1) than after 3 months (5) and after 6 months (6). No significant difference was noted regarding Kapandji score between 3 months and 6 months.

**Table (6)** Kapandji score before, after 3 & 6 months in the studied patients

<i>Kapandji score</i>	Median (range)	P value
<b>Before</b>	1 (1 - 2) <sup>a</sup>	$<0.001$
<b>After 3 months</b>	5 (4 - 7) <sup>b</sup>	
<b>After 6 months</b>	6 (4 - 7) <sup>b</sup>	

Friedman's test was used. Post-hoc analysis was done using Bonferroni method. Different letters indicate significant pair

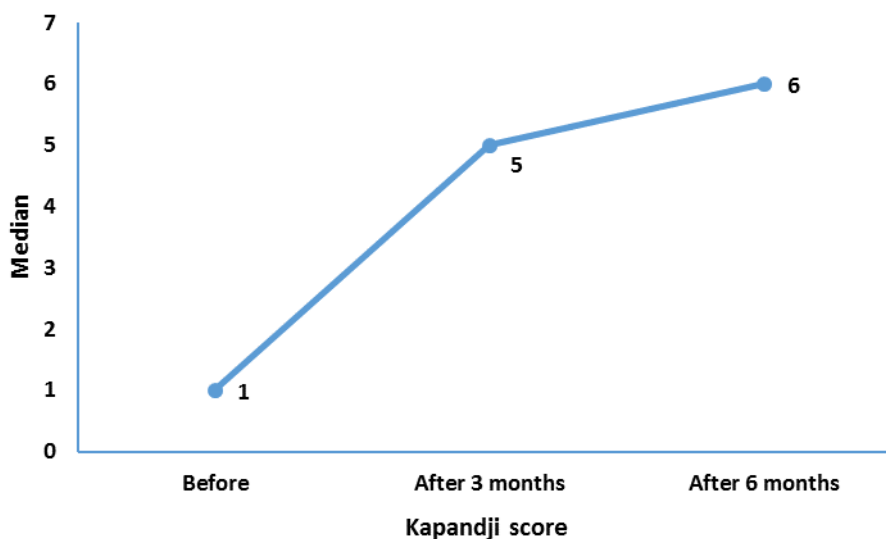


Figure (27) Kapandji score before, after 3 & 6 months in the studied patients

❖ **VAS score before surgery, after 3 months and 6 months in the studied patients**

- There were no significant differences between VAS score before surgery, after 3 months, and after 6 months. P value was 0.5.

Table (7) VAS score before, after 3 & 6 months in the studied patients

VAS score	Median (range)	P value
Before	1 (0 - 2)	0.5
After 3 months	1 (0 - 2)	
After 6 months	1 (0 - 2)	

Friedman's test was used.

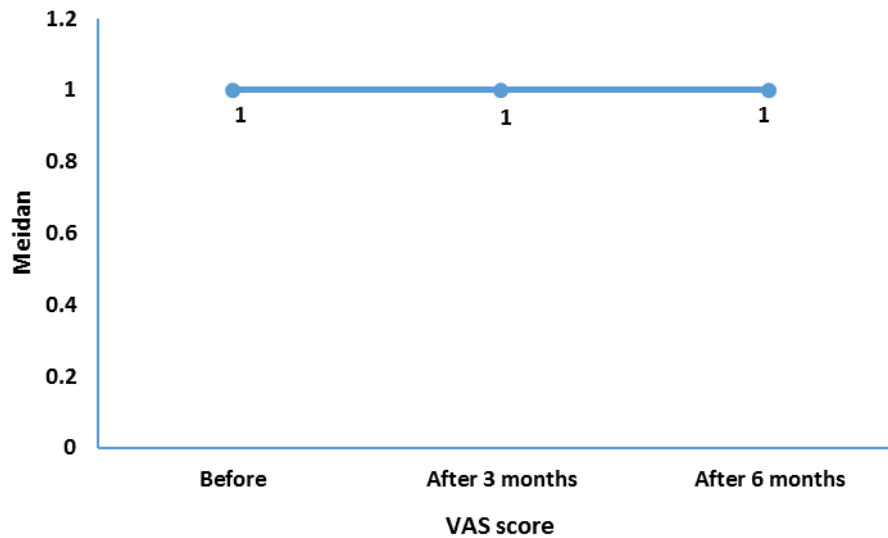


Figure (28) VAS score before, after 3 & 6 months in the studied patients

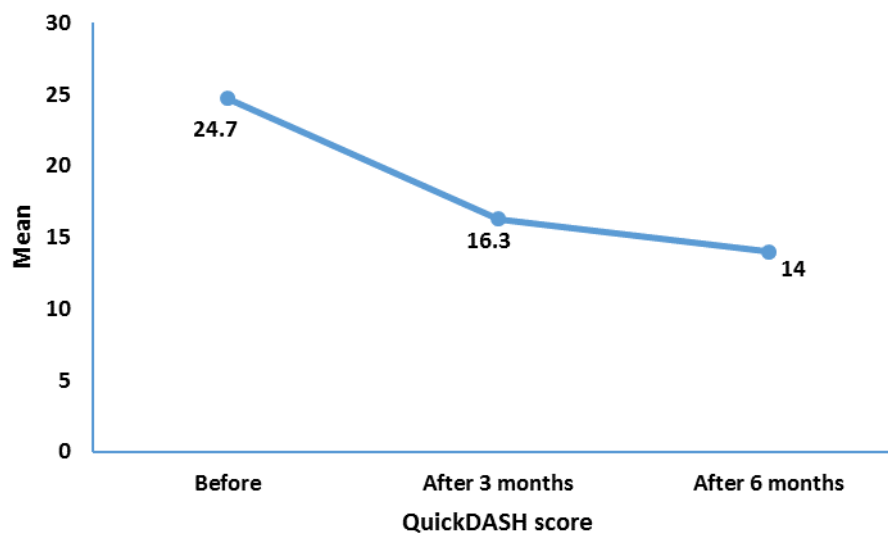
❖ **QuickDash score before surgery, after 3 months and 6 months in the studied patients**

- There was an overall significant difference between QuickDash score before surgery, after 3 months, and after 6 months, P value was  $<0.001$ . Post hoc analysis revealed that mean QuickDash score was significantly higher before surgery (24.7) than after 3 months (16.3) and after 6 months (14). Also, QuickDash score at 3 months was significantly higher (16.3) than after 6 months (14).

**Table (8)** QuickDASH score before, after 3 & 6 months in the studied patients

<i>QuickDASH score</i>	<b>Mean ±SD</b>	<b>P value</b>
<b>Before</b>	24.7 ±5.7 <sup>a</sup>	<0.001
<b>After 3 months</b>	16.3 ±4.1 <sup>b</sup>	
<b>After 6 months</b>	14 ±4.4 <sup>c</sup>	

Repeated measures ANOVA was used. Post-hoc analysis was done using Bonferroni method. Different letters indicate significant pair



**Figure (29)** QuickDASH score before, after 3 & 6 months in the studied patients

## **DISCUSSION**

The thumb is an important part of the hand that is responsible for most daily activities. The importance of the actions of this finger becomes clearer when we know that the usual daily activities are significantly lost in the absence of opposition. Therefore, patients who lose their ability to Pronation, Abduction, and Flexion due to traumatic thumb injury are significantly limited in their daily activities. <sup>(42)</sup>

Loss of thumb opposition represents a significant functional deficit to the hand. Given the importance of restoring opposition of the thumb, it is not surprising that many different tendon sources and transfer insertion sites have been described in attempts to confront this problem. To treat this condition we used Riordan method in which FDS tendon of the ring finger is used as motor unit donor in cases of low median nerve palsy.

Median nerve injury results in a serious functional set back to the patient. Since these nerve injuries occur more commonly in men who are physiologically active, athletic and in the most productive age group; this may cause considerable morbidity, if not managed efficiently.

The main goal of this study was to the outcome of tendon transfer for restoration of opposition in cases of low median nerve injury regarding hand grip and range of motion and functional outcome.

The mean age of the studied patients was 29 years, with a standard deviation of 11 years. Regarding gender, 63.3% were males, and 36.7% were females. The most frequent mode of injury was traumatic (66.7%), followed by iatrogenic and self-injuries (16.7% for each). Regarding laterality of injured hand, more than two thirds of patients had right hand injury, and 26.7% had left hand injury. The mean time between injuries to

surgery was 17 months, with a standard deviation of 3 months. The mean time between injuries to surgery was 17 months, with a standard deviation of 3 months.

We used the Kapandji score used to measure opposition of the thumb. There was an overall significant difference between Kapandji score before surgery, after 3 months, and after 6 months, P value was <0.001. Post-hoc analysis revealed that median Kapandji score was significantly lower before surgery (1) than after 3 months (5) and after 6 months (6). No significant difference was noted regarding Kapandji score between 3 months and 6 months.

We used the visual analog scale (VAS) as a pain rating scale. There were no significant differences between VAS score before surgery, after 3 months, and after 6 months. P value was 0.5.

We used the Quick Disabilities of the Arm, Shoulder, and Hand (QuickDASH) score (in which a score of 0 means no disability and a score of 100 means complete disability). There was an overall significant difference between QuickDash score before surgery, after 3 months, and after 6 months, P value was <0.001. Post hoc analysis revealed that mean QuickDash score was significantly higher before surgery (24.7) than after 3 months (16.3) and after 6 months (14). Also, QuickDash score at 3 months was significantly higher (16.3) than after 6 months (14).

Skie et al <sup>(43)</sup> compared different methods and compared the strengths and weaknesses of Flexion, Extension, Abduction, and Pulp pinching. Finally, they concluded that the Riordan method FDS tendon opponensplasty was superior to all other methods. These results are somehow in line with our findings indicating the effectiveness of FDS tendon opponensplasty in patients with low median nerve palsy.



Jafari et al <sup>(44)</sup> compared the results of opponensplasty by Riordan and Burckhalter techniques. They reported Riordan method brought excellent results for 60.4% of patients and the Burckhalter method was successful for all patients and 80.6% of them had excellent results.

In another study by Lemonas et al <sup>(45)</sup>, the success of Opponensplasty was assessed using the EIP method and it was reported that the results of the Burckhalter method acceptable for FDS tendon Opponensplasty. These results are also in line with the finding of our study but here we used FDS tendon for opponensplasty.

Cooney et al <sup>(46)</sup> reported that flexor digitorum superficialis of the long and ring fingers are suitable for low median nerve palsy when strength was required. He preferred EIP transfer when only thumb mobility was desired.

A comparison study of EIP and flexor digitorum superficialis (FDS) opponensplasty in 166 patients with median nerve paralysis of varied etiology was done by Anderson et al. <sup>(47)</sup> FDS was used for the transfer in 116 patients, whereas, EIP was used in rest 50. They showed that the EIP opponensplasty was best in supple hands and FDS opponensplasty was more suitable for less pliable hands. An ulnar nerve injury associated with a high median nerve injury limits the choice of available motors for opponensplasty. The flexor digitorum superficialis, palmaris longus and abductor digiti minimi are all not available and EIP is the obvious tendon of choice for an opponensplasty.

Median is a mixed nerve responsible for sensory innervation in the radial three and a half digits which contribute to the ever so important pinch area of the hand. It also supplies the intrinsic musculature involving complex movements of the thumb, thereby the prognosis following repair

remains unpredictable. Brown et al. <sup>(48)</sup> reported the results of surgery in 272 upper extremity nerve injuries and found that neuroorrhaphy of median nerve (38 repairs) resulted in partial functional recovery in half of the patients, whereas, other half had no functional benefit. He also suggested that tendon transfers for median nerve palsy have shown fairly good results in irreparable lesions of the nerve as 27 out of total 31 patients showed significant improvement.

Care must be taken to take a small portion of the extensor expansion along with the tendon or it may be too short. After detachment, the extensor expansion must be repaired carefully to avoid extensor lag of the index finger. In FDS opponensplasty, the dissection should not be taken too far laterally while detaching the donor tendon to avoid damage to the lateral bands of the extensor expansion leading to inadequate extension of the DIP joint of the ring finger. The volar incision permits direct visualization of the FDS tendon without the need to carry the dissection laterally. Detachment of FDS decreases power grip, but we have not measured this. The power of the motor should be enough to restore ante-position but not to prevent adduction.

**Challenge** traumatic low median nerve palsy required opponensplasty are small number. This is because most patients who experience traumatic low median nerve injury never lose opposition because of the intact ulnar nerve, which frequently anomalously innervates the ulnar muscles – a fact that was recently noted by Davis. <sup>(49)</sup> The Weaknesses of the study include the relatively small number of cases and the fact that the ‘power’ of opposition was not assessed.

## **RECOMMENDATION**

We found that FDS opponensplasty give better results in low median nerve palsy. The volar oblique incision offers clear visualization when detaching the FDS tendon, reducing the incidence of flexion deformity of the ring finger.

## **SUMMARY & CONCLUSION**

Thumb opposition is a critical operation of thumb. Median nerve palsy interferes with a large number of ordinary activities such as opposition.

There are many potential causes of median nerve palsy, and thus a lack of opposition. These include acute median nerve laceration or damage from trauma as well as chronic median nerve compression from carpal tunnel syndrome, pronator syndrome, or cervical radiculopathy.

Opponensplasty for low median nerve injury is performed with various techniques. It is a commonly used tendon transfer to restore thumb opposition. The flexor digitorum superficialis (FDS) of the ring finger is the most commonly used donor motor unit in cases of low median nerve palsy.

Thirty patients treated with FDS Opponensplasty the patient's ages ranged from 18-40 years, Assessment of opposition by Kapandji score and assessment of degree of pain by VAS and hand grip by QuickDASH score. All the patients will have nerve conduction and electromyogram, Clinically examination after 2 weeks and removal of the skin suture then at 4 weeks removal of the slab and allow for controlled range of motion, and at 3, 4 months postoperatively .

Kapandji score used to measure opposition of the thumb. There was an overall significant difference between Kapandji score before surgery, after 3 months, and after 6 months, P value was <0.001. Post-hoc analysis revealed that median Kapandji score was significantly lower before surgery (1) than after 3 months (5) and after 6 months (6). No significant

difference was noted regarding Kapandji score between 3 months and 6 months.

The visual analog scale (VAS) used as a pain rating scale. There were no significant differences between VAS score before surgery, after 3 months, and after 6 months. P value was 0.5.

There was an overall significant difference between QuickDash score before surgery, after 3 months, and after 6 months, P value was <0.001. Post hoc analysis revealed that mean QuickDash score was significantly higher before surgery (24.7) than after 3 months (16.3) and after 6 months (14). Also, QuickDash score at 3 months was significantly higher (16.3) than after 6 months (14).

We found that FDS opponensplasty give better results in low median nerve palsy. The volar oblique incision offers clear visualization when detaching the FDS tendon, reducing the incidence of flexion deformity of the ring finger.

## REFERENCES

- 1- **El-Beshbishy RA, Abdel-Hamid GA.** Variations of the abductor pollicis longus tendon: anatomic study. *Folia Morphol (Warsz)* 2013;72(2):161e166.
- 2- **Royle ND.** An operation for paralysis of the intrinsic muscles of the thumb. *JAMA* 1983;111:612–3.
- 3- **Olave E, Prates JC, Del Sol M, et al.** Distribution patterns of the muscular branch of the median nerve in the thenar region. *J Anat* 1995;186(Pt 2):441–6.
- 4- **North ER, Littler JW.** Transferring the flexor superficialis tendon. Technical considerations in the prevention of proximal inter phalangeal joint disability. *J Hand Surg* 2011;5:498–501.
- 5- **Lee Y.K. (2019)** Anatomy and Biomechanics. In: Woo S. (eds) *The Thumb*. Springer, Singapore part I , chapter 2 . [https://doi.org/10.1007/978-981-10-4400-7\\_2](https://doi.org/10.1007/978-981-10-4400-7_2) .
- 6- **Ross AC. In: Standring S, editor.** *Wrist and hand*. Gray's anatomy. 41st ed. Amsterdam: Elsevier; 2016.p. 862–894 e1.
- 7- **McFadden D, Bracht MS.** Sex and race differences in the relative lengths of metacarpals and metatarsals in human skeletons. *Early Hum Dev.* 2009; 85(2):117–24.
- 8- **Bettinger PC, Berger RA.** Functional ligamentous anatomy of the trapezium and Trapeziometacarpal joint (gross and arthroscopic). *Hand Clin.* 2001;17(2):151–68.
- 9- **Schmidt HM, Lanz U.** *Thumb*. In: *Surgical anatomy of the hand*. Stuttgart: Georg Thieme Verlag; 2004. p. 85–113.
- 10- **Leversedge FJ.** Anatomy and pathomechanics of the thumb. *Hand Clin.* 2008;24(3):219–29.

- 11- **Gupta S, Michelsen-Jost H.** Anatomy and function of the thenar muscles. *Hand Clin.* 2012;28(1):1–7.
- 12- **Esplin VS, Tencer AF, Hanel DP, Cosio MQ.** Restoration of function of the thumb flexor apparatus requires repair of the oblique and one adjacent flexor tendon pulley. *J Orthop Res.* 1996;14(1):152–6.
- 13- **Johnson EO, Vekris MD, Zoubos AB, Soucacos PN.** Neuroanatomy of the brachial plexus: the missing link in the continuity between the central and peripheral nervous systems. *Microsurgery.* 2006;26:218–29.
- 14- **Duncan SF, Saracevic CE, Kakinoki R.** Biomechanics of the hand. *Hand Clin.* 2013;29(4):483–92.
- 15- **Posner MA, Kapila D.** Restoration of opposition. *Hand Clin.* 2012;28(1):27–44.
- 16- **Chadderdon RC, Gaston RG.** Low Median Nerve Transfers (Opponensplasty). *Hand Clin.* 2016 Aug;32(3):349-59.
- 17- **Lee Y.K. (2019)** Nerve problems In: Woo S. (eds) *The Thumb.* Springer, Singapore part V , chapter 14 .  
[https://doi.org/10.1007/978-981-10-4400-7\\_2](https://doi.org/10.1007/978-981-10-4400-7_2) .
- 18- **Mahmoud M, Abdel-Ghani H, Elfar JC.** New flap for widening of the web space and correction of palmar contracture in complex clasped thumb. *J Hand Surg.*2013;38(11):2251–6.
- 19- **Terrono AL, Rose JH, Mulroy J, Millender LH.** Camitz palmaris longus abductorplasty for severe thenar atrophy secondary to carpal tunnel syndrome. *J Hand Surg.* 1993;18(2):204–6.
- 20- **Taylor J, Casaletto JA.** Absence of extensor indicis tendon complicating reconstruction of the extensor pollicis longus. *J Hand Surg Eur Vol.* 2017;42(5): 528–9.

- 21- **Davis T.R.** . Principles of tendon transfers of median, radial, and ulnar nerve. 7th ed. Philadelphia: Elsevier; 2017.
- 22- **Anderson GA, Lee V, Sundararaj GD.** Opponensplasty by extensor indicis and flexor digitorum superficialis tendon transfer. *J Hand Surg.* 1992;17(6):611–4.
- 23- **Koo CC, Roberts AH.** The palmaris longus tendon. Another variation in its anatomy. *J Hand Surg.*1997;22(1):138–9.
- 24- Rymer B, Thomas PB. The Camitz transfer and its modifications: a review. *J Hand Surg Eur Vol.* 2016;41(6):632–7.
- 25- **Uysal AC, Alagoz MS, Tuccar E, Sensoz O, Tekdemir I.** The vascular anatomy of the abductor digiti minimi and the flexor digiti minimi brevis muscles. *J Hand Surg.* 2005;30(1):172–6.
- 26- **Kehr, P.H., Liverneaux, P. David P. Green, Robert N. Hotschkiss, William C. Pederson, Scott W. Wolfe** (eds) (2005): *Green’s operative hand surgery, 6th edn. Low Median Nerve Palsy Part V chapter 34 page 1093* (2011).
- 27- **Abou-Al-Shaar H, Dorius GT, Morton DA, Mahan MA.** Distal nerve transfer for thenar palsy: A cadaveric study. *Clin Anat.* 2020 Apr;33(3):414-418.
- 28- **Beutel BG, Melamed E, Rettig ME.** The Stener Lesion and Complete Ulnar Collateral Ligament Injuries of the Thumb A Review. *Bull Hosp Jt Dis* (2013). 2019 Mar;77(1):11-20.
- 29- **Anderson GA, Lee V, Sundararaj GD.** Extensor indicis proprius opponensplasty. *J Hand Surg.* 1991;16(3):334–8.
- 30- **Burkhalter W, Christensen RC, Brown P.** Extensor indicis proprius opponensplasty. *J Bone Jt Surg Am.* 1973;55(4):725–32.
- 31- **Kraker M, Selles RW, Zuidam JM, Molenaar HM, Stam HJ, Hovius SE.** Outcome of flexor digitorum superficialis



- opponensplasty for Type II and IIIA thumb hypoplasia. *J Hand Surg Eur Vol.* 2016;41(3):258–64.
- 32- **Jacobs BTT.** Opposition of the thumb and its restoration. *J Bone Joint Surg Am.* 1960;42(A):12.
- 33- **Jensen EG.** Restoration of opposition of the thumb. *Hand.* 1978;10(2):161–7.
- 34- **Terrono AL, Rose JH, Mulroy J, Millender LH.** Camitz palmaris longus abductorplasty for severe thenar atrophy secondary to carpal tunnel syndrome. *J Hand Surg.* 1993;18(2):204–6.
- 35- **Foucher G, Malizos C, Sammut D, Braun FM, Michon J.** Primary palmaris longus transfer as an opponensplasty in carpal tunnel release. A series of 73 cases. *J Hand Surg.* 1991;16(1):56–60.
- 36- **Park IJ, Kim HM, Lee SU, Lee JY, Jeong C.** Opponensplasty using palmaris longus tendon and flexor retinaculum pulley in patients with severe carpal tunnel syndrome. *Arch Orthop Trauma Surg.* 2010; 130(7):829–34.
- 37- **Wissinger HA, Singsen EG.** Abductor digiti quinti opponensplasty. *J Bone Jt Surg Am.* 1977; 59(7): 895–8.
- 38- **Elhassan B, Steinmann SP.** Entrapment neuropathy of the ulnar nerve. *J Am Acad Orthop Surg.* 2007 Nov; 15(11):672-81.
- 39- **Kapandji A I.** Clinical test of apposition and counter-apposition of the thumb [in French] *Ann Chir Main.* 1986;5:67–73.
- 40- **Delgado D.A., Lambert B.S., Boutris N., McCulloch P.C., Robbins A.B., Moreno M.R., Harris J.D.** Validation of Digital Visual Analog Scale Pain Scoring with a Traditional Paper-based Visual Analog Scale in Adults. *J. Am. Acad. Orthop. Surg. Glob. Res. Rev.* 2018; 2:e088.

- 41- **Hudak P L Amadio P C Bombardier C**; The Upper Extremity Collaborative Group (UECG). Development of an upper extremity outcome measure: the DASH (disabilities of the arm, shoulder and hand) [corrected] *Am J Ind Med* 1996;29:602–608.
- 42- **Rahnamayan S, Tizhoosh HR, Salama MM**. Opposition-based differential evolution. *IEEE Trans Evol Comput*. 2008;12:64–79.
- 43- **Skie MC, Parent T, Mudge K, Dai Q**. Kinematic analysis of six different insertion sites for FDS opponensplasty. *Hand*. 2010;5:261–266.
- 44- **Jafari D, Yeganeh A, Shariatzadeh H**. Assessment of results of opponensplasty in patients in shafa rehabilitation center between 1974-2005. *Razi J Med Sci*. 2007;14:75–80.
- 45- **Lemonas P, Laing T, Ghorbanian S, Malahias M, Ragoowansi R**. Extensor indicis proprius opponensplasty-the burkhalter revisited. *J Hand Microsurg*. 2012;4:47–49.
- 46- **Cooney WP**. Tendon transfer for median nerve palsy. *Hand Clin*. 1988;4(2):155e165.
- 47- **Anderson GA, Lee V, Sundararaj GD**. Opponensplasty by extensor indicis and flexor digitorum superficialis tendon transfer. *J Hand Surg Br*. 1992;17(6):611e614.
- 48- **Brown PW**. The time factor in surgery of upper-extremity peripheral nerve injury. *Clin Orthop Relat Res*. 1970;68:14e21.
- 49- **Davis TRC**. *Green's Operative Hand Surgery*. 4th edn. Philadelphia: Elsevier Churchill Livingstone; 2005. Median nerve palsy; pp. 1131–59.

كان هناك فرق كبير بشكل عام بين درجة QuickDash قبل الجراحة ، وبعد ٣ أشهر ، وبعد ٦ أشهر ، كانت قيمة  $P < 0.001$  كشف التحليل اللاحق أن متوسط نقاط QuickDash كان أعلى بكثير قبل الجراحة (٢٤,٧) منه بعد ٣ أشهر (١٦,٣) وبعد ٦ أشهر (١٤). أيضاً ، كانت نتيجة QuickDash في ٣ أشهر أعلى بكثير (١٦,٣) مما كانت عليه بعد ٦ أشهر (14).

وجدنا أن عملية استعادة حركه اصبع الابهام تعطي نتائج أفضل في إصابة العصب الاوسط السفليه. يوفر الفتح الامامى المائل رؤيه اوضح عند فصل وتر العضلة المثنية السطحية ، مما يقلل من حدوث تشوه انتنائي لإصبع البنصر.

## الملخص العربي

تعتبر حركة اصبع الإبهام عملية حساسة للإبهام. يؤثر إصابه العصب الاوسط فى عدد كبير من الأنشطة العادية مثل حركة اصبع الابهام .

هناك العديد من الأسباب المحتملة لإصابه العصب الاوسط ، وبالتالي عدم وجود حركة لاصبع الابهام. وتشمل الاسباب المحتملة لتمزق العصب الاوسط الحاد أو التلف الناتج عن الصدمة وكذلك ضغط العصب الاوسط المزمن من متلازمة النفق الرسغي أو متلازمة الكعب أو التهاب الاعصاب العنقية.

يتم إجراء عملية استعادة حركة اصبع الابهام لإصابة العصب الاوسط السفليه بتقنيات مختلفة. يعتبر نقل الاوتار شائع الاستخدام لاستعادة حركة اصبع الابهام. تعتبر العضلة المثنية السطحية لإصبع البنصر هي الوحدة الحركية الأكثر استخدامًا في حالات إصابة العصب الاوسط السفليه.

تم علاج ثلاثين مريضًا باستخدام عملية استعادة حركة اصبع الابهام لإصابة العصب الاوسط السفليه ، تراوحت أعمار المرضى بين ١٨-٤٠ عامًا ، وتقييم حركة اصبع الابهام من خلال درجة كابانديج وتقييم درجة الألم عن طريق المقياس التناظري البصري وقبضة اليد عن طريق درجة QuickDASH. سيخضع جميع المرضى للتوصيل العصبي والتخطيط الكهربائي للعضلات ، والفحص السريري بعد أسبوعين وإزالة خياطة الجلد ثم بعد ٤ أسابيع إزالة الجبيرة والسماح بنطاق الحركة المتحكم فيه خلال ٣ ، ٤ أشهر بعد الجراحة.

تستخدم درجة كابانديج لقياس حركة اصبع الابهام. كان هناك فرق معنوي إجمالي بين درجة كابانديج قبل الجراحة ، وبعد ٣ أشهر ، وبعد ٦ أشهر ، كانت قيمة  $P < 0.001$ . كشف التحليل اللاحق أن متوسط درجة كابانديج كان أقل بشكل ملحوظ قبل الجراحة (١) منه بعد ٣ أشهر (٥) وبعد ٦ أشهر (٦). لم يلاحظ أي فرق كبير فيما يتعلق بدرجة كابانديج بين ٣ أشهر و ٦ أشهر.

المقياس التناظري البصري المستخدم كمقياس لتصنيف الألم. لم يكن هناك فروق ذات دلالة إحصائية بين نتيجة المقياس التناظري البصري قبل الجراحة وبعد ٣ أشهر وبعد ٦ أشهر. كانت قيمة  $P 0.5$ .



# استعادة حركة ضم الابهام في حالات اصابة العصب الاوسط السفلية

رسالة دكتوراه في جراحة العظام

مقدمة من

**أحمد ابراهيم محمد القاضي**

بكالوريوس الطب والجراحة  
ماجستير جراحة العظام

تحت إشراف

**أ.د/ وائل عبد العزيز قنديل**

أستاذ جراحة العظام  
كلية الطب - جامعة بنها

**أ.م.د/ اسامة محمد عيسوي**

أستاذ مساعد جراحة العظام  
كلية الطب - جامعة بنها

**أ.م.د/ اسلام عبد الشافي طبل**

أستاذ مساعد جراحة العظام  
كلية الطب - جامعة بنها

**كلية الطب**

**جامعة بنها**

2021